

Plastibell circumcision supported by a calcium-alginate fibre dressing to reduce bleeding

Ravisankar G. Pillai & Ziad Al Naieb

To cite this article: Ravisankar G. Pillai & Ziad Al Naieb (2015) Plastibell circumcision supported by a calcium-alginate fibre dressing to reduce bleeding, Arab Journal of Urology, 13:3, 179-181, DOI: [10.1016/j.aju.2015.04.001](https://doi.org/10.1016/j.aju.2015.04.001)

To link to this article: <https://doi.org/10.1016/j.aju.2015.04.001>



© 2015 Arab Association of Urology



Published online: 05 Apr 2019.



Submit your article to this journal [↗](#)



Article views: 332



View related articles [↗](#)




View Crossmark data [↗](#)



Arab Journal of Urology
(Official Journal of the Arab Association of Urology)

www.sciencedirect.com



PEDIATRIC UROLOGY
ORIGINAL ARTICLE

Plastibell circumcision supported by a calcium-alginate fibre dressing to reduce bleeding



Ravisankar G. Pillai *, **Ziad Al Naieb**

Department of Urology, Royal Bahrain Hospital, Bahrain

Received 25 February 2015, Received in revised form 25 March 2015, Accepted 26 April 2015
Available online 19 May 2015

KEYWORDS

Plastibell;
Circumcision;
Neonates;
Calcium alginate;
Bleeding

Abstract Objective: To assess the benefit of a new technique of a Plastibell circumcision supported by a ventral calcium-alginate fibre dressing, to reduce bleeding from the frenular vessels, the commonest complication of Plastibell circumcision.

Patients and methods: This was a retrospective study of 200 neonates circumcised in the Royal Bahrain Hospital over a 2-year period from 2012 to 2014. They had a standard Plastibell circumcision, but a calcium-alginate fibre dressing (Hypo-sorb, Plastod, Italy) was placed over the glans and under the foreskin, to help control bleeding from the frenular vessels.

Results: Circumcision using the calcium-alginate fibre dressing reduced the bleeding complication rate to zero. The delayed separation of the bell was 2.9% when using the new technique and 2.5% from our previous data. There were no cases of urinary retention reported, compared to two in the previous results.

Conclusion: A Plastibell circumcision supported by the calcium-alginate fibre dressing was a safe technique to reduce bleeding.

© 2015 Arab Association of Urology. Production and hosting by Elsevier B.V. This is an open access article under the CC BY-NC-ND license (<http://creativecommons.org/licenses/by-nc-nd/4.0/>).

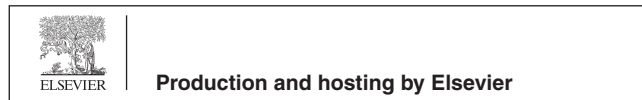
Introduction

World-wide, circumcision is one of the commonest surgical procedures in the neonatal period. The vast majority of neonatal circumcisions are done for religious or cultural reasons. The advantages and disadvantages of neonatal circumcision remain a matter of debate [1]. The main medical benefit of circumcision is considered to be the reduction in relative risk of UTI during infancy. Six UTIs can be prevented for every

* Corresponding author.

E-mail address: gopakravi@gmail.com (R.G. Pillai).

Peer review under responsibility of Arab Association of Urology.



complication endured, and almost two complications can be expected for every case of penile cancer prevented [2]. Currently, the Plastibell method is frequently used for neonatal circumcision, as it is quicker and has fewer late complications [3–5]. The common complications reported with Plastibell circumcision are problems with the ring (3.6%), and bleeding (3%). Here we analyse a new technique which can reduce bleeding-related complications and give the best cosmetic results.

Patients and methods

After obtaining approval from the local ethics committee, we retrospectively analysed the results of 200 neonatal circumcisions at the Royal Bahrain Hospital between 2013 and 2014, for which we used a new technique in which the Plastibell circumcision was supported by a ventral calcium-alginate fibre dressing. The mean (SD, range) age of the patients was 5.85 (1–30) days.

Procedure

The neonates were not fed for 2 h before circumcision. After placing an infant on a circumcision-restraint board, the skin was prepared with a povidone-iodine (10%) solution. A dorsal nerve block was administered using 0.2 mL/kg of 2% lidocaine, with a 27-G needle, and a delay of 3 min allowed before starting the procedure (Fig. 1A). The first step was to hold the prepuce between two haemostatic forceps to either side of the midline, and make a compressed skin line by crushing with another haemostatic forceps. A dorsal slit was then made through the compressed skin line (Fig. 1B). The prepuce was pulled back and cleaned using the povidone-iodine solution. The entire prepuce, sulcus and frenular attachment was examined (Fig. 1C). Retraction of the prepuce will rupture the frenulum, causing bleeding, if the frenular attachment is closer to the urethral meatus. Bleeding over the frenular area was assessed and a small compression applied for some time. A Plastibell with a calcium-alginate fibre dressing on the ventral aspect (Hypo-sorb, Plastod, Italy) was placed over the glans and under the foreskin (Fig. 1D). This helps to control the bleeding from the frenular vessels. The prepuce is then returned to its anatomical position. The bell is held in position between the haemostat forceps by an assistant. A silk suture is tied around the entire foreskin, which will fall off (after necrosis) within several days (Fig. 1E). The excess skin over the bell is excised using scissors (Fig. 1F). The parents of the patients were informed to return if the interval before bell separation was > 10 days. However, there was no further intervention unless the bell remained for > 15 days.

The ventral dressing is a sterile non-adhesive advanced wound dressing formed by a soft and

conformable net of pure calcium-alginate microfibrils. The highly hydrophilic fibres swell during the absorption of exudate, forming a firm gel which fills the wound without adhesion to it.

The patient is advised to apply mupirocin cream to the wound two to three times daily until the bell falls off. The bell, along with dressing, usually falls within 4–10 days.

Results

This method of circumcision was associated with no bleeding complications, whereas previously in our department the commonest complication associated with Plastibell circumcision was bleeding from the frenular vessels, occurring in 5% of circumcisions during 2011–2012. The rate of delayed separation or migration of the bell was 2.9% in the present study, compared to 2.5% in our previous data. There were no cases of urinary retention, compared to two previously.

Discussion

Routine circumcision is becoming more acceptable world-wide, and according to numerous studies the Plastibell technique is considered to be the safest procedure for neonatal circumcision, with overall complications being very rare. Many of the studies show that the Plastibell method is an acceptable option for circumcision even up to middle childhood. The common reported complications include haemorrhage, infection, sepsis, meatal ulceration, a retained bell, and poor cosmetic results. During a Plastibell circumcision the complete release of adhesion of the prepuce to the glans, including the frenular area, is very important for obtaining a good cosmetic result and avoiding the complication of the bell compressing the urethral meatus. The choice of a correctly sized Plastibell is also important to avoid compression of the glands and any oedema, thus leading to difficulty in urination. The main problem that the surgeon faces is that when the prepuce is retracted properly, the risk of bleeding from the frenular vessels can be unpredictable, and if incorrectly retracted the bell can compress the urethral meatus, leading to a poor cosmetic result. If the bell is too large or too small there might be a proximal or distal dislocation.

Bleeding was a significant complication in many previous studies, with rates of 18–44% [6,7], and these studies showed that there was no difference in the infection rate in a Plastibell group compared to standard circumcision, with rates of 4–14% [7–11]. In the present study there were no reported infections requiring a hospital visit. The mean (range) time required for bell separation was 6 (4–15) days. The rate of delayed separation (> 10 days) of the retained bell was 2.9%, compared

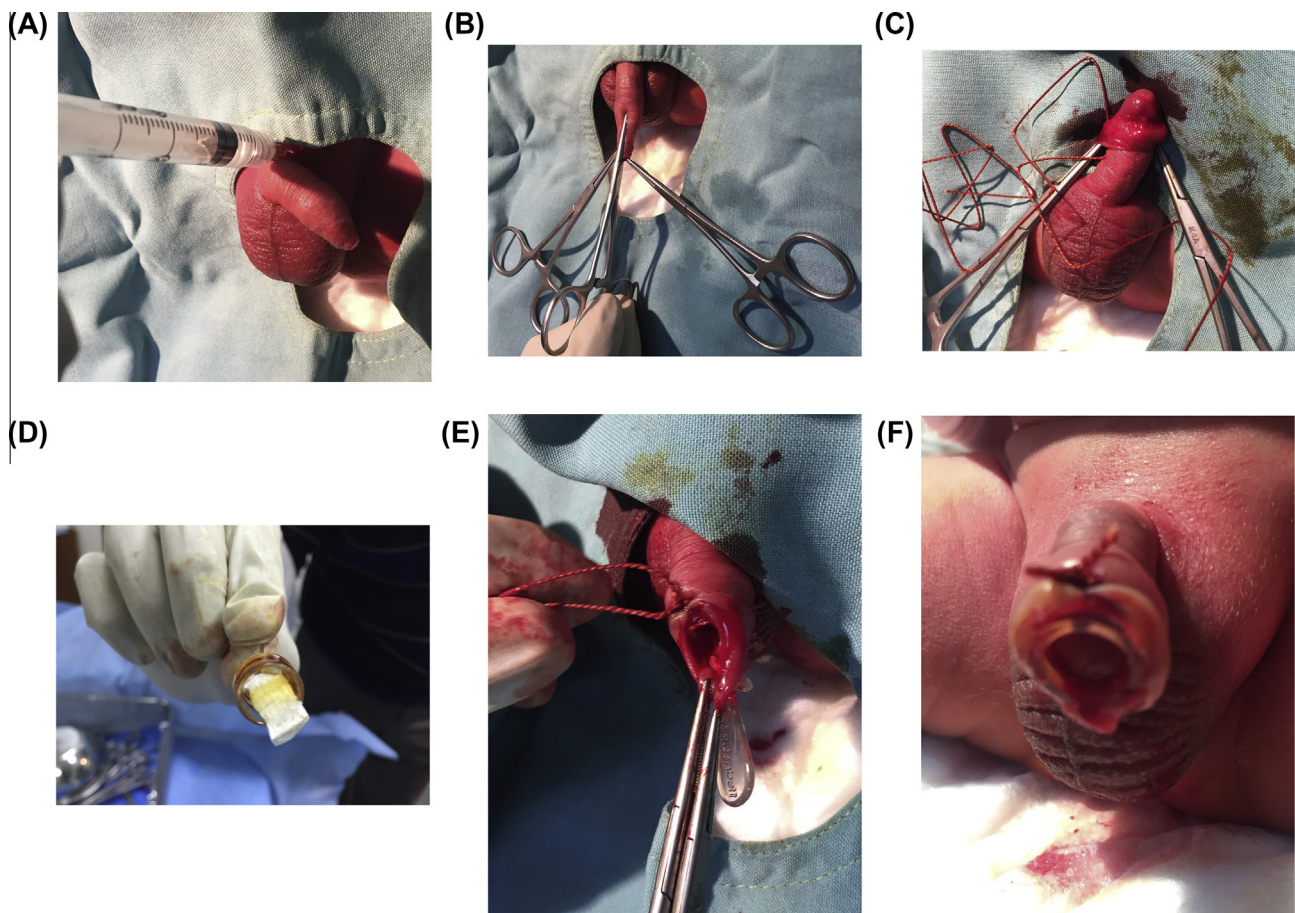


Figure 1 (A) A dorsal nerve block dorsal is applied. (B) A slit is made through a compressed skin line. (C) The prepuce is retracted and the frenular area examined. (D) The alginate dressing is placed inside the ventral aspect of the bell. (E) The silk suture is positioned and tied. (F) The excess skin over the bell is removed.

to a previous rate of 2.5%, but no bell was retained for > 15 days.

In conclusion, a Plastibell circumcision supported by the calcium-alginate fibre dressing is a safe modification to standard Plastibell circumcision to reduce bleeding-related complications.

Conflict of interest

None.

Source of funding

None.

References

- [1] Palit V, Menebhi DK, Taylor I, Young M, Elmasry Y, Shah T. A unique service in UK delivering Plastibell circumcision. Review of 9 year results. *Pediatr Surg Int* 2007;**23**:45–8.
- [2] Christakis DA, Harvey E, Zerr DM, Feudtner C, Wright JA, Connell FA. A trade-off analysis of routine newborn circumcision. *Pediatrics* 2000;**105**:246–9.
- [3] Fraser IA, Allen MJ, Bagshaw PF, Johnstone M. A randomized trial to assess childhood circumcision with the Plastibell device compared to a conventional dissection technique. *Br J Surg* 1981;**68**:593–5.
- [4] Mak YL, Cho SC, Fai MW. Childhood circumcision: conventional dissection or Plastibell device—a prospective randomized trial. *The Hong Kong Practitioner* 1995;**17**:101–5.
- [5] Bastos Netto JM, de Araújo Jr JG, de Almeida Noronha MF, Passos BR, de Bessa Jr J, Figueiredo AA. Prospective randomized trial comparing dissection with. *J Pediatr Urol* 2010;**6**:572–7.
- [6] Mousavi SA, Salehifar E. Circumcision complications associated with the Plastibell device and conventional dissection surgery: a trial of 586 infants of ages up to 12 months. *Adv Urol* 2008;**606**:123.
- [7] Lazarus J, Alexander A, Rode H. Circumcision complications associated with the Plastibell device. *South Afr Med J* 2007;**97**:192–3.
- [8] Sørensen SM, Sørensen MR. Circumcision with the Plastibell device. A long-term follow-up. *Int Urol Nephrol* 1988;**20**:159–66.
- [9] Shah T, Raistrick J, Taylor I, Young M, Menebhi D, Stevens R. A circumcision service for religious reasons. *BJU Int* 1999;**83**:807–9.
- [10] Manji KP. Circumcision of the young infant in a developing country using the Plastibell. *Ann Trop Paediatr* 2000;**20**:101–4.
- [11] Holman JR, Lewis EL, Ringle RL. Neonatal circumcision techniques. *Am Fam Physician* 1995;**52**:519–20.