



# **Photographic Changes in the Alar Base Width in Using Modified Alar Cinch Technique Following Lefort I Osteotomy: A Narrative Review**

**Mehrnoush Momeni<sup>1</sup> and Seyed Mostafa Mortazavi<sup>2\*</sup>**

<sup>1</sup>Department of Oral and Maxillofacial Surgery, Craniomaxillofacial Research Center, School of Dentistry, Tehran University of Medical Sciences, Tehran, Iran.

<sup>2</sup>Department of Oral and Maxillofacial Surgery, School of Dentistry, Tehran University of Medical Sciences, Tehran, Iran.

## **Authors' contributions**

*This work was carried out in collaboration between both authors. Author MM designed the study, performed the statistical analysis, wrote the protocol and wrote the first draft of the manuscript. Author SMM managed the analyses of the study, managed the literature searches. Both authors read and approved the final manuscript.*

## **Article Information**

DOI: 10.9734/JPRI/2019/v28i330205

### Editor(s):

(1) Dr. Syed A. A. Rizvi, Department of Pharmaceutical Sciences, Nova Southeastern University, USA.

### Reviewers:

(1) K. Ramesh Kumar, Kaloji Narayana Rao University of Health Sciences, India.

(2) Sajeela Ismail, Educare Institute of Dental Sciences, India.

Complete Peer review History: <http://www.sdiarticle3.com/review-history/49885>

**Review Article**

**Received 22 April 2019**

**Accepted 24 June 2019**

**Published 05 July 2019**

## **ABSTRACT**

**Introduction:** The alar cinch techniques are used in order to control the alar base widening following Le Fort I surgeries. Three main alar cinch techniques include classic, Shams-Kalantar and modified techniques. There is scarcity of scientific literature regarding the modified technique therefore, this review was conducted to assess the photographic changes in the alar base width following Lefort I osteotomy using the modified Cinch technique.

**Methods:** Literature search was performed using the "Modified", "alar base", "Lefort I osteotomy" keywords in the Web of Science, PubMed and Scopus databases. Articles published between 2010 till Jun 2019 were included in the study. Identified articles were screened based on inclusion and exclusion criteria by two researchers independently and the identified articles were discussed afterwards.

**Results:** The search yielded 7 articles in English language. The findings of all the included studies

\*Corresponding author: E-mail: [Drmo\\_mortazavi@yahoo.com](mailto:Drmo_mortazavi@yahoo.com)

revealed that the modified technique was as effective as the classic and Shams-Kalantar techniques. Furthermore, it was reported that the modified technique was more effective in controlling the alar base width in case of alar base flaring.

**Conclusion:** The findings of this review revealed that the modified cinch technique was more effective compared to other techniques. In conclusion, the advantages of the modified technique including better control of the alar base width and improved patient satisfaction following orthognathic surgery out power its disadvantages.

*Keywords: Modified; alar base width; lefort I osteotomy.*

## 1. INTRODUCTION

Lefort I osteotomy is the most common type of surgery in the field of orthognathic surgery [1]. The secondary nasolabial changes following Lefort I osteotomy are well identified and include widening of the alar base, upturning of nasal tip, thinning and straightening of the upper lip [2]. The most common indication for Lefort I osteotomy is correction of hypoplastic maxilla in class III skeletal malocclusion [3]. The alar base tends to widen in Lefort I osteotomy due to the incision of the soft tissue and dissection of paranasal musculature. Cinch suture of the alar base helps control the unfavorable changes in the alar base soft tissue and maxillary movement following Lefort I osteotomy [4]. Different cinch techniques, including classical technique, Shams-Kalantar and modified techniques, exist for the controlling of the alar base width. In the classic technique, unabsorbable suturing takes place in fibroareolar tissue under both alae intraorally using the Adson tissue forceps (Figure-of-1) while the nasofacial fold is pressed from the outside of the mouth [5-6]. The Shams-Kalantar technique is a more controllable accurate technique compared to the classic technique. In the Shams-Kalantar technique the suture passes by an incision inside the mouth through the fibroareolar tissue and para-alae musculature passing the inferolateral border of the alar skin fold and reinserted back into the oral cavity through the same puncture site and is tied to the suture with the same procedure from the other side in the midline. A slight overcorrection is recommended in Shams-Kalantar technique as there is a predictable postoperative relapse due to the resolution of edema and muscular tension [7]. The modified technique is a new technique that is implemented by creating a hole in the infrolateral border of the piriform rim [8].

Various studies have been conducted on the Shams-Kalantar technique. For instance, in a study by Westermarck et al. (1991), the cinch suture was found to be effective in controlling

alar base flaring in 123 patients who underwent Lefort I osteotomy [9]. In a study by Rauso (2009) the classic technique was compared with the Shams-Kalantar technique and found that the post-operative alar base width changes were less in Shams-Kalantar technique compared to the classic technique [10]. In contrast, few studies have assessed the effectiveness of modified cinch technique, therefore this review was conducted to assess the photographic changes of alar base width using modified cinch technique following Lefort I osteotomy.

## 2. METHODS

**Objective:** This narrative review was conducted to assess the photographic changes in alar base width using the modified cinch technique following Lefort I osteotomy.

**Search strategy:** The keywords that were used in this study included “modified”, “Lefort I osteotomy” and “alar base”. The Web of science, PubMed and Scopus databases were searched and articles published from 2010 till Jun 2019 were included in the review.

**Inclusion criteria:** In order to select articles, the titles were first screened based on relevance to the objectives. Then the abstract of the articles with relevant titles were assessed for relevance with the objectives of the review, including the assessment of modified cinch technique, and the relevant articles were included in the review.

**Exclusion criteria:** Articles with irrelevant title, incomplete methodology, or studies that were published as abstract as well as duplicate articles were excluded from the review.

**Data extraction:** Two independent reviewers screened the articles based on inclusion and exclusion criteria. The identified articles were then shared and the number of articles were finalized after discussion between reviewers. The findings of the studies were then categorized

based on orthognathic surgery, Lefort I osteotomy definition and the cinch technique used, including modified technique following Lefort I osteotomy. Finally, the findings of the studies were summarized in a table.

### 3. RESULTS

The primary search yielded 45 articles, among which 7 articles were relevant to the topic and thus were included in the review.

#### 3.1 Orthognathic Surgery

Orthognathic surgery is a corrective surgery for deformities in the jaw and teeth. In orthognathic surgery the corrections are made to the jaw skeleton [11]. The term orthognathic has originated from the Greek word "Orthos" meaning "to correct" and "Gnathic" meaning "jaw". This surgery is performed by an oral and maxillofacial (OMS) surgeon and an orthodontist in hospital setting in order to reposition the jaw by means of surgical plates or frames, screws and wires [12-13]. The main goal for this surgery is to correct severe jaw and tooth malformations, that result in difficulties in daily living tasks including speech, mastication or sleep [14]. Due to these difficulties, patient might experience chronic head ache, pain in temporomandibular joint (TMJ) and periodontal complaints. The duration of orthognathic surgery is between one and three hours [15]. The surgery duration is timed after reaching the predicted alignment of the teeth. This surgery requires general anesthesia, which adds to the complications if the surgery including pain, swelling, bleeding, infection and reactions to anesthesia. Theoretically, skeletal and gum injuries as well as paresthesia are among the probable complications of orthognathic surgery. Patient is usually hospitalized for one or two days following orthognathic surgery followed by a 6-week recovery period at home. Although in most cases occlusion is recovered, mandibular range of motion might be temporarily or permanently restricted due to jaw fixation and surgical trauma [16-17].

#### 3.2 Definition of Lefort I osteotomy

Lefort I osteotomy is the most common orthognathic surgery. Lefort I permits the movement of upper jaw in three planes and might be performed alone or in combination with mandibular osteotomy to correct dentofacial malformations [18]. In 1901 Rene Le Fort described the maxillary fracture planes and

categorized them into three classes. In Le Fort type I fracture, the fracture line separates maxilla from the piriform and anterior wall of sinuses and pterygoid plates. Type II Le Fort fracture, also called pyramidal fracture, includes maxilla, nasal structure and inferior rim while type III Le Fort fracture includes maxilla, nose, orbit and zygoma, which indicate complete midface separation from base of skull [19].

The first maxillary osteotomy was performed by Von Langenbeck in Germany in 1859 in order to access nasopharyngeal polyp [20]. Lefort I osteotomy was first performed to correct midface deformity by Wassmund [21]. In 1965, Obwegeser described Lefort I osteotomy to reposition maxilla by complete immobilization of maxilla [22-23] but the Lefort I osteotomy did not become popular till Bell reported significant maxillary perfusion in Lefort I osteotomy in 1973 [24].

The most common indication for Lefort I osteotomy is the correction of hypoplastic maxilla with class III skeletal pattern. Maxillary hypoplasia may occur in different planes which require anterior or inferior repositioning of maxilla. Lefort I osteotomy may also be indicated in the correction of vertical maxillary excess deformity, another common dentofacial deformity, in which the gummy smile is over exposed or may result in mastication defects [25].

Maxilla and mandible are placed in a new position after orthognathic surgery and the soft tissue also undergoes changes. In general, after surgery, the facial attractiveness is improved and the favorable skeletal changes reflect in the soft tissue appearance [26].

#### 3.3 Lefort I Technique

In Lefort I osteotomy a 5-10 cm vestibular incision is performed in labial sulcus above the mucogingival junction and first molars under general anesthesia and with the application of local anesthesia (Lidocaine with 1/100000 Epinephrine). The periosteal elevator is used to elevate subperiosteal flap and to expose anterior maxillary wall, infra-orbital foramen, piriform rim and zygomaticomaxillary suture. Then the anterior nasal spine (ANS) periosteum is elevated using elevator Freer and the piriform rim edge is exposed. Then the location 5 mm above the canine root apex and first molar is marked and osteotomy is performed bilaterally parallel to

the occlusal plane from tuberosity to buttress of maxilla and the piriform rim. After performing nasal septum and lateral nasal osteotomy and separating pterygomaxillary junction, down-fracture is made to correct bone interactions in the posterior and tuberos regions. In the next step, fixation is performed after performing favorable repositioning [27]. After soft tissue incision in Lefort I osteotomy and dissection of the paranasal musculature, the alar base tends to widen [28-29].

The alar base widening will be minimal if cinch suture is performed [30-31]. There are various techniques for performing cinch suture. Changes in the nasal morphology are related to the direction and amount of maxillary movement. Most of these changes occur in superior/anterior or anterior maxillary movements [32]. Different soft tissue changes happen in labial and nasal structures after Lefort I osteotomy. Maxillary movement affects the inferior area of the nasal dorsum, which results in alar base widening regardless of the direction of maxillary movement. Furthermore, shortening of the columella and alar cartilage and reduced nose tip projection take place in most cases. Superior maxillary repositioning results in the elevation of nasal tip and widening of the alar base and reduced nasolabial angle. Anterior maxillary repositioning may result in advancement of the upper lip and subnasal tissue as well as thinning of the upper lip and widening of the alar base and increase in supra tip break and closed nasolabial angle [33-35]. Cinch suture in alar base area helps to control the unfavorable changes in soft tissue and nasal base following Lefort I osteotomy and maxillary repositioning [36]. Alar base widening relates to the nasal base width before surgery, which might look attractive to the patient [37-38]. For instance, in a patient with narrow nose and projected nasal dorsum,

the alar base widening will result in improved facial attractiveness [37]. In contrast, widening of the alar base after Lefort I osteotomy and superior maxillary repositioning in a patient with wide alar base before surgery might result in unfavorable changes and aged appearance of the patient due to the deepening of the nasolabial fold [35,39]. In performing maxillary surgery, surgeon should predict the possible facial and nasolabial changes based on photographs taken before surgery [34].

### 3.4 Modified Technique

Maxillary surgeries and especially Lefort I osteotomy are the techniques of choice for maxillary deformities and result in significant nasal changes. For instance, widening of alar base and probable changes in the structure of nasal tip, which are related to the direction of bone repositioning, soft tissue repositioning and thickening of the skin, are among the consequences of maxillary surgeries [30]. A surgical technique for controlling the widening of nasal base is the nasal base cinch technique. The modified cinch technique is a new alar cinch technique that is executed by performing a hole in the inferolateral border of piriform rim. The suture passes the fibroareolar and musculature inside the mouth in piriform area and is tied. Similar procedure is performed on the other side (Fig. 1).

### 3.5 Usage of the Modified Technique Following Lefort I osteotomy in the Reviewed Studies

In this section of the manuscript the findings regarding the effectiveness of modified technique after Lefort I osteotomy in the included studies are summarized (Table 1).

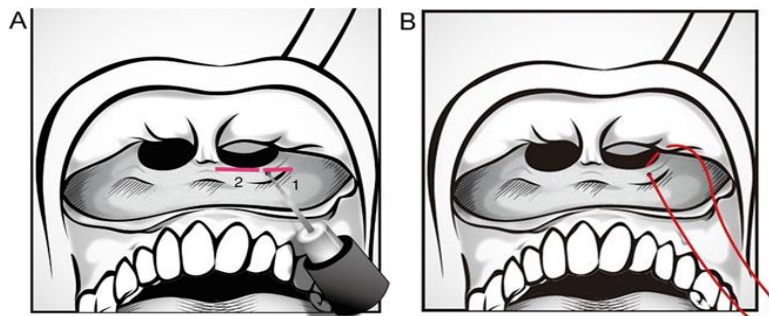


Fig. 1. Modified technique procedure

**Table 1. Modified technique following Lefort I osteotomy in the included studies**

<b>Author (year)</b>	<b>Title</b>	<b>Findings</b>	<b>Reference</b>
Rauso et al. (2010)	Comparison of two techniques of cinch suturing to avoid widening of the base of the nose after Le Fort I osteotomy	The outcomes of the modified technique were more stable than the classic technique.	11
Ritto et al. (2011)	Comparative analysis of two different alar base sutures after Le Fort I osteotomy: randomized double-blind controlled trial	The modified technique was more effective compared to the classic technique.	40
Nirvikalpa et al. (2013)	Comparison between the classical and a modified trans-septal technique of alar cinching for Le Fort I osteotomies: a prospective randomized controlled trial	The modified technique was more effective in maxilla in reduction of alar base widening.	5
Liu et al. (2014)	Modified versus classic alar base sutures after Le Fort I osteotomy: a systematic review	The modified technique had a better control on alar base width.	30
Chen et al. (2015)	Effects of two alar base suture techniques suture techniques on nasolabial changes after bimaxillary orthognathic surgery in Taiwanese patients with class III malocclusions	The conventional technique was effective in columellar elongation. In contrast the modified technique was more effective in NLA elongation in response to skeletal movement in ANS and also was more effective in the upper lip and nasal surgery.	41
Yen et al. (2016)	Modified alar base cinch suture fixation at the bilateral lower border of the piriform rim after a maxillary Le Fort I osteotomy	The modified technique resulted in control of the alar base widening.	8
Shaik et al. (2017)	Evaluation of modified nasal to oral endotracheal tube switch—For modified alar base cinching after maxillary orthognathic surgery	The modified technique was more effective on alar base and prevented alar flare.	42

A total of 7 articles regarding the effect of modified technique following Lefort I osteotomy were included in the review. Among the included articles, the study by Rauso et al. was performed on two groups of patients (20 patients in each group) undergoing classic method and modified technique. The study revealed that 3 patients in the classic group did not have widening of alar base while the alar base widening was not observed in 14 patients in the modified group [11].

Yen et al. (2016) compared the modified technique (17 patients) with classic technique following Lefort I osteotomy (advancement with or without impaction) and found that the modified technique could better control alar flare compared to the classic technique. In the study by Yen et al., the cinch suture was performed separately to a stable location in piriform in right and left sides of nasal alae [8].

In a clinical trial performed by Nirkalpa et al. on two groups of patients; 31 patients in traditional classic technique group and 31 patients in the modified technique group, who underwent Lefort I osteotomy. The baseline alar base width in the traditional and modified groups were  $29.76 \pm 1.901$  mm and  $29.79 \pm 3.141$  mm respectively. The alar base width after surgery in the traditional and modified technique groups were  $32.41 \pm 1.858$  mm and  $29.94 \pm 2.568$  mm respectively. Mean alar base widening in the traditional group was  $2.661 \pm 0.800$  mm while the mean alar base widening in the modified group was  $0.145 \pm 2.050$  mm. the findings of this study revealed the effectiveness of modified technique over the traditional technique [5].

In the randomized clinical trial performed by Chen et al. the effects of conventional and modified alar base techniques were compared on 60 patients who underwent Lefort I osteotomy. The post-surgical changes in skeletal and soft tissue were assessed using composite pyramidal tomography and three-dimensional stereo photography. The alar base widening in the conventional group was  $1.31 \pm 0.31$  mm and the columellar length expansion was  $1.60 \pm 0.97$  mm while in the modified group the upper lip height increased by  $1.87 \pm 0.81$  mm and prolabial width was decreased by  $1.56 \pm 0.76$  mm [41].

#### 4. DISCUSSION

In this review on 7 articles, all the articles reported superiority for modified technique over

the other cinch techniques including classic and Shams-Kalantar techniques. In a study by Howley et al. (2010) the classic technique was reported to be less effective than the modified technique and therefore the modified technique was recommended in that article [31]. In the study by Shams et al. the disadvantages, including difficulty in performing correct and symmetrical suture during the application of Adson tissue forceps and the asymmetric pulling of the tissues in both sides, were reported for classic technique. Shams et al. stated that the asymmetrical tissue inclusion in the classic technique results in asymmetric tension in the two sides of alar base and causes horizontal discrepancy. Furthermore, if the fibroareolar suture in one side is made higher or lower than the other side, the alar base would be located higher or lower in one side and results in vertical discrepancy [7]. One of the disadvantages of both classic and Shams-Kalantar techniques is the length of the suture that results in reduction in the tension and loosening of the thread in long term. Furthermore, the effect of nasotracheal tube on the midline suture results in weakening of the suture tension after extubation, which is another disadvantage of the classic and Shams-Kalantar techniques [7].

Based on the findings of the studies by Yen et al. [8] and Shaik et al. [42] one of the main advantages of the modified technique was better control against alar flaring in the alar base. The studies by Howley et al. [31] and Khamashta-Ledezma et al. [43] revealed that the classic cinch technique was not effective in controlling the alar base width. In the study by Betts et al. the classic technique was found to reduce alar based compared to performing no cinch suture at all [44]. The modified technique tends to obtain a more stable and firm tissue in the Cinch suture in alar base. Passing the suture from the fibroareolar tissue from outside the mouth provides a firm subdermal tissue, which results in a better control of alar base after orthognathic surgery [7, 40].

The modified technique that was used in the study by Yen et al. involved separate sutures in right and left sides of the nasal alae to the stable and firm piriform area. One of the reasons for the use of the inferolateral border of the piriform rim in this technique is to reduce the effect of nasotracheal tube on the suture. This suture results in a better symmetry and tissue tension downwards and towards the midline, which resembles the normal soft tissue insertion. The

length of the suture results in the weakening of the thread. In the classic and Shams-Kalantar techniques the length of the suturing thread might reach 60 mm, due to the one or two side suturing, but the length of the suture thread would reach 10 mm in each side in the modified technique. Therefore, the modified technique results in a better stability during the recovery period after surgery. As mentioned before, the modified technique results in the use of a shorter suture and reduces the effect of nasotracheal tube without remaining facial scar. Furthermore, the suture is fixed to the hard and osseous tissue and minimizes the post-surgical changes [8].

## 5. CONCLUSION

The findings of this review revealed that all the included studies insisted on the superiority of modified technique over other cinch techniques, including classic and Shams-Kalantar techniques. Although no disadvantage was reported for the modified technique in the studies, the modified technique may also have some disadvantages, including difficulty in performing the suture due to the fixation of maxilla which might elongate the duration of surgery. Considering the positive effects of modified technique in the control of alar base widening and improving patient satisfaction from orthognathic surgery, the disadvantages of this technique are negligible. It is suggested that the efficacy of the modified technique be assessed in original research or clinical trial studies with large sample sizes to be able to assess the effect of the extent of maxillary repositioning on the alar base width. Furthermore, there is a need for larger studies to compare the effect of modified technique with other cinch techniques in terms of preventing alar base width changes in patients with greater maxillary vertical height.

## CONSENT

It is not applicable.

## ETHICAL APPROVAL

It is not applicable.

## ACKNOWLEDGEMENTS

This paper was extracted from thesis of Dr Mortazavi, approved by Department of Oral and

Maxillofacial Surgery, Tehran University of Medical Sciences, Tehran, Iran.

## COMPETING INTERESTS

Authors have declared that no competing interests exist.

## REFERENCES

1. Marchica P, Bassetto F, Vindigni V, et al. Endoscopic sinus surgery associated with rhinoseptoplasty: A case-control study. *Plast Reconstr Surg Glob Open*. 2018;6(9):e1922. (Published 2018 Sep 14)  
DOI:10.1097/GOX.0000000000001922
2. Murrell GL. Rhinoplasty and functional endoscopic sinus surgery. *Plast Surg Int*. 2011;473481.  
DOI:10.1155/2011/473481
3. Bellinga RJ, Capitán L, Simon D, Tenório T. Technical and clinical considerations for facial feminization surgery with Rhinoplasty and related procedures. *JAMA Facial Plast Surg*. 2017;19(3):175–181.  
DOI:10.1001/jamafacial.2016.1572
4. Nellis JC, Ishii M, Bater KL, et al. Association of rhinoplasty with perceived attractiveness, success and overall health. *JAMA Facial Plast Surg*. 2018;20(2):97–102.  
DOI:10.1001/jamafacial.2017.1453
5. Sajjadi M, Honarvar H, Basiri-Moghadam K, Nazemi H, Mirhaghi A. Comparison of merocel and regular tampon regarding comfort and problems of patients after septo-rhinoplasty surgery. *J Birjand Univ Med Sci*. 2010;17(4):249-256.
6. Cosmetic plastic surgery research; Statistics and trends for 2001-2008. Available from: <http://www.cosmeticplasticsurgerystatistics.com/statistics.html>.
7. Rowenna D. Nose no problem; 2008. Available: <http://www.newstatesman.com/society/2008/03/nose-iranreligious-lenehan>
8. Parrilla C, Artuso A, Gallus R, Galli J, Paludetti G. The role of septal surgery in cosmetic rhinoplasty. *Acta Otorhinolaryngol Ital*. 2013;33(3):146–153.
9. Stenner M, Rudack C. Diseases of the nose and paranasal sinuses in child. *GMS Curr Top Otorhinolaryngol Head Neck Surg*. 2014;13:Doc10. Published 2014 Dec 1.  
DOI:10.3205/cto000113

10. Westermarck AH, Bystedt H, von Konow L, Sällström KO. Nasolabial morphology after Le Fort I osteotomies Effect of alar base suture. *International Journal of Oral and Maxillofacial Surgery*. 1991;20(1):25-30.
11. Rauso R, Gherardini G, Santillo V, Biondi P, Santagata M, Tartaro G. Comparison of two techniques of cinch suturing to avoid widening of the base of the nose after Le Fort I osteotomy. *Br J Oral Maxillofac Surg*. 2010;48(5):356-9.  
DOI: 10.1016/j.bjoms.2009.08.007.
12. Mathes SJ. *Plastic surgery, philaphia, saunders*. 2006;2:517-518.
13. Goldwyn RM. Is there plastic surgery in the Edwin Smith Papyrus? *Plast Reconstr Surg*. 1982;70(2):263-4.
14. Sushruta. *Sushruta Samhita (English translation by KL Bhishagratna)*; 1998. Calcutta, India: Kavirraj Kunjalal Publishing; 1907-17.
15. Koçak I, Gökler O, Şentürk E. Is osteoplasty with unilateral osteotomy effective in the correction of the crooked nose?. *J Craniofac Surg*. 2018;29(2):491-494.  
DOI: 10.1097/SCS.0000000000004130.
16. What is nose osteotomy and how is it done?. Available:<http://amadegahclinic.com/2019/02/18>
17. Khamashta-Ledezma L, Naini FB, Manisali M. Review of nasal changes with maxillary orthognathic surgery. *J Istanb Univ Fac Dent*. 2017;51(3Suppl1):S52–S61. (Published 2017 Dec 2)  
DOI:10.17096/jiufd.09789
18. Fonseca RJ MR, Turvey TA. *Oral and maxillofacial surgery*. 3. third ed. 2018;153.
19. Le Fort R. *Fractures de la machoire superieure*. Cong intenat de med C-r, Sect de chir. 1900;ger 275-8.
20. von Langenbeck B. *Beiträge zur Osteoplastik*: Druck von G. Reimer; 1859.
21. Wassmund M. *Frakturen und Luxationen des Gesichtsschädels: Unter besonderer Berücksichtigung der Komplikationen des Hirnschädels; ihre Klinik und Therapie; praktisches Lehrbuch*: Meusser; 1927.
22. Obwegeser H. *Surgery of the maxilla for the correction of prognathism*. *Schweizerische Monatsschrift für Zahnheilkunde = Revue mensuelle suisse d'odonto-stomatologie*. 1965;75:365.
23. Obwegeser hl. *Surgical correction of small or retrodisplaced maxillae the "dish-face" deformity*. *Plastic and reconstructive Surgery*. 1969;43(4):351-65.
24. Bell WH. *Biologic basis for maxillary osteotomies*. *American journal of physical anthropology*. 1973;38(2):279-89.
25. Fonseca RJ MR, Turvey TA. *Oral and maxillofacial surgery*. 3. third ed. 2009;153.
26. Kinnebrew MC, Emison JW. *Simultaneous maxillary and nasal reconstruction: an analysis of twenty-five cases*. *Journal of Cranio-Maxillofacial Surgery*. 1987;15:312-25.
27. Fonseca RJ MR TT. *Oral and maxillofacial surgery*. 3. third ed. 2018;161-6.
28. Rauso R, Tartaro G, Tozzi U, Colella G, Santagata M. *Nasolabial changes after maxillary advancement*. *Journal of Craniofacial Surgery*. 2011;22(3):809-12.
29. Vasudavan S, Jayaratne YS, Padwa BL. *Nasolabial soft tissue changes after Le Fort I advancement*. *Journal of Oral and Maxillofacial Surgery*. 2012;70(4):e270-e7.
30. Liu X, Zhu S, Hu J. *Modified versus classic alar base sutures after LeFort I osteotomy: a systematic review*. *Oral surgery, oral medicine, oral pathology and oral radiology*. 2014;117(1):37-44.
31. Howley C, Ali N, Lee R, Cox S. *Use of the alar base cinch suture in Le Fort I osteotomy: is it effective?* *British Journal of Oral and Maxillofacial Surgery*. 2011;49(2):127-30.
32. Collins PC, Epker BN. *The alar base cinch: A technique for prevention of alar base flaring secondary to maxillary surgery*. *Oral Surg Oral Med Oral Pathol*. 1982;53(6): 549-53.
33. Schendel SA, Carlotti Jr AE. *Nasal considerations in orthognathic surgery*. *American Journal of Orthodontics and Dentofacial Orthopedics*. 1991;100(3):197-208.
34. Mitchell C, Oeltjen J, Panthaki Z, Thaller SR. *Nasolabial aesthetics*. *Journal of Craniofacial Surgery*. 2007;18(4):756-65.
35. O'Ryan F, Schendel S. *Nasal anatomy and maxillary surgery. I. Esthetic and anatomic principles*. *The International journal of adult orthodontics and orthognathic surgery*. 1989;4(1):27-37.
36. Guymon M, Crosby D, Wolford L. *The alar base cinch suture to control nasal width in maxillary osteotomies*. *The International Journal of Adult Orthodontics and Orthognathic Surgery*. 1988;3(2):89.
37. Schendel SA, Delaire J. *Facial muscles: form, function, and reconstruction in*



- dentofacial deformities. Surgical Correction of Dentofacial Deformities: New Concepts Philadelphia: WB Saunders. 1985:259-315.
38. Westermarck AH, Bystedt H, von Konow L, Sällström KO. Nasolabial morphology after Le Fort I osteotomies Effect of alar base suture. International journal of oral and maxillofacial surgery. 1991;20(1):25-30.
39. Rosenberg A, Muradin MS, vd Bilt A. Nasolabial esthetics after Le Fort I osteotomy and VY closure: A statistical evaluation. The effect of alar cinch sutures and VY closure versus simple closing sutures after Le Fort I osteotomies on nasolabial esthetics and dynamics. 2002:25.
40. Yen CY, Kuo CL, Liu IH, Su WC, Jiang HR, Huang IG, et al. Modified alar base cinch suture fixation at the bilateral lower border of the piriform rim after a maxillary Le Fort I osteotomy. Int J Oral Maxillofac Surg. 2016;45(11):1459-63.
41. Ritto FG, Medeiros PJ, de Moraes M, Ribeiro DP. Comparative analysis of two different alar base sutures after Le Fort I osteotomy: randomized double-blind controlled trial. Oral Surg Oral Med Oral Pathol Oral Radiol Endod. 2011;111(2):181-9. DOI: 10.1016/j.tripleo.
42. Nirvikalpa N, Narayanan V, Wahab A, Ramadorai A. Comparison between the classical and a modified trans-septal technique of alar cinching for Le Fort I osteotomies: a prospective randomized controlled trial. Int J Oral Maxillofac Surg. 2013;42(1):49-54. DOI: 10.1016/j.ijom.2012.05.027.
43. Chen CY, Lin CC, Ko EW. Effects of two alar base suture techniques suture techniques on nasolabial changes after bimaxillary orthognathic surgery in Taiwanese patients with class III malocclusions. Int J Oral Maxillofac Surg. 2015;44(7):816-22. DOI: 10.1016/j.ijom.2015.03.003
44. Shaik TNS, Meka S, Ch PK, et al. Evaluation of modified nasal to oral endotracheal tube switch-For modified alar base cinching after maxillary orthognathic surgery. J Oral Biol Craniofac Res. 2017; 7(2):75–80. DOI:10.1016/j.jobcr.2017.03.008

© 2019 Momeni and Mortazavi; This is an Open Access article distributed under the terms of the Creative Commons Attribution License (<http://creativecommons.org/licenses/by/4.0>), which permits unrestricted use, distribution, and reproduction in any medium, provided the original work is properly cited.

*Peer-review history:*

*The peer review history for this paper can be accessed here:  
<http://www.sdiarticle3.com/review-history/49885>*