



Histopathological Impact of Profenofos on Ovary of the Freshwater Fish *Notopterus notopterus*

Safiya Tazeen^{1*} and R. S. Kulkarni¹

¹Department of P.G Studies and Research in Zoology, Gulbarga University, Kalaburagi, 585106, India.

Authors' contributions

This work was carried out in collaboration between both authors. Both authors read and approved the final manuscript.

Article Information

DOI: 10.9734/AJRIZ/2018/v1i229682

Editor(s):

(1) Dr. Farzana Khan Perveen, Associate Professor, Department of Zoology, Shaheed Benazir Bhutto University (SBBU), Pakistan.

Reviewers:

(1) Ana Maria Costa, Instituto Português do Mar e da Atmosfera, Portugal.

(2) M. Thangaraj, Annamalai University, India.

(3) Bashir Lawal, Federal University of Technology Minna, Nigeria.

Complete Peer review History: <http://www.sciencedomain.org/review-history/27969>

Original Research Article

Received 16 September 2018

Accepted 07 December 2018

Published 26 December 2018

ABSTRACT

The presence of pesticide in the environment, owing to extensive use in agriculture and their low degradation capacity, are the potential toxicological concern for fish. Histological studies have been extensively used as biomarker in the assessment of the health of fish exposed to the pesticides, both in the laboratory as well as in the field studies. In the present study adult freshwater teleost fish *Notopterus notopterus* of nearly similar weight and length were exposed to sub lethal concentration of 0.7 pp LC50 of profenofos (Curacron 50% EC) during reproductive phase. For histological changes the treated fish groups were compared with the control group. Marked changes such as atretic follicles, degenerative changes in oocyte were observed.

Keywords: Ovary; reproductive phase; profenofos; histology; *N. notopterus*.

1. INTRODUCTION

Owing to rapid raise in the industrialization and human population, the pollution of aquatic

ecosystem has become a universal phenomenon in the present day world [1]. Aquatic contamination of the pesticides causes acute and chronic poisoning of fish and other organism.

*Corresponding author: Email: tazeenchishti@gmail.com;

The early life stages of fish, like eggs and larvae are particularly sensitive to contaminant [2].

Modern agricultural practices, even though contributed to improve the crop production, also widely polluted the aquatic environment [3]. Fish reproduction is effected by the direct or indirect exposure to aquatic pollution [4]. There have been few attempts to study the influence of aquatic toxicants on the fish reproduction. It is understood that the reproduction is essential to the survival and continue the race, therefore in this review, influence of aquatic pollutants on the reproductive system is considered.

Histopathological effects of pesticides in fishes have been studied intensively. In contrast to dramatic fish kills, the effects of sublethal concentrations of pesticides are more subtle and go largely unseen and unregulated. Sublethal concentrations of pesticides do not cause immediate death, but can obstruct the biology of the organism in other ways and can eventually impact the survival of the species. Laboratory studies show that sublethal concentrations of pesticides can affect many aspects of salmon biology, including a number of behavioral effects [5].

In addition to changes in behavior, exposure to relatively low concentrations of pesticides can disrupt the immune system and have serious negative impacts on the immune system. Such disturbance results in the onset of disease and even death. Fish and other organisms are especially vulnerable to endocrine-disrupting effects during the early stages of development, pesticide at low concentrations may act as mimics or blockers of sex hormones, causing abnormal sexual development, feminization of males, abnormal sex ratios, and unusual mating behavior. The unique plasticity of sex discrimination in fish suggests that these animals may be very susceptible to disturbance of sexual characteristics by pollutants. Pesticides can also interfere with other hormonal action, such as thyroid functioning and bone development.

Pesticides can ultimately influence fish by interfering with their food supply or altering the aquatic habitat, even when the concentrations are too low to affect the fish directly. Such indirect effects greatly reduce the abundance of food organisms which in turn reduces the growth and probability of survival of the fish.

Reproduction is one the fundamental characters of living things. It is the ability of an organism to produce copies of it to continue the species [6]. Reproduction is a record established between the organism and the environment where the organism lives. It is well known that intrinsic factors like sex and size of the individual greatly influence various physiological processes in variety of organisms. Although the gonadal cycle of Indian freshwater fishes have been extensively studied [7], only few species have been worked out for their reproductive cycle.

The availability of any fish species in large number is basically dependent upon their reproductive potency and also indices that the prevailing environment influencing gonadal development and spawning is favorable [8]. The fish *N. notopterus* locally known as "chambari" selected for the present study is available in large number throughout the year in most of the aquatic bodies of the study area suggests that the environmental condition of this area is favorable for reproduction. Hence the overall aim of the present study is to determine the impact of profenofos (Curacron 50% EC) on reproduction of the fish *N. notopterus*. The present study will focus on the impact of pesticide on ovary during different reproductive phases of seasonal reproductive cycle of the freshwater fish *N. notopterus*.

2. MATERIALS AND METHODS

Adult healthy, teleost fishes, *N. notopterus* were collected from local fisherman and taken to the laboratory and kept in glass aquaria of 50L capacity. The fish were first acclimatized under laboratory conditions in glass aquaria 15 days prior to the experiment.

The fishes were divided into two groups in glass aquaria. Ten fish were used for each group and they were exposed to 0.07 ppm of profenofos (Curacron 50% EC) for different reproductive phases (Preparatory, Prespawning, Spawning and Post spawning phase) of reproductive cycle of the freshwater fish *N. notopterus* for 15 days in each reproductive phase. After every alternate day egg white and goat liver was given to the fish, and water was renewed to avoid contamination and toxicant was added into the water. At the expiry of each experimental period, control and exposed fish were processes simultaneously.

3. HISTOPATHOLOGICAL EXAMINATION

To examine the extent of cellular damage caused by the sublethal concentration of profenofos (Curacron 50% EC) in the ovary of the control and experimental fish *N. notopterus* during the reproductive phase were fixed in Bouin's fluid for 24 hrs. After 24 hrs the tissues were dehydrated in graded series of alcohol, cleared in xylene and embedded in paraffin wax (58^o-60^oc). By using a rotary microtome, 4-6µ thick sections were taken and the sections were deparaffinized in xylene, passed through descending grades of alcoholic series and then washed with distilled water then the sections were stained with haematoxylin and counterstained with aqueous eosin. Stained sections were mounted in DPX for microscopic observations.

Seasonal Gonadal Cycle of *N. notopterus*:

The seasonal reproductive cycle of *N. notopterus* was studied first before utilizing this fish for the present study to identify the condition of gonadal development in four generally applied phases.

The detection of reproductive phase during one year period is based on the morphological examination of gonads in both male and female. Collection of the fish during rainy season was hard since the fish goes to the deeper part of the water body. However, they use to be found near the weeds and their submerged branches of acacia plants. This may because of their participation in the spawning activity.

The study of the gonads is based on the morphological examination in both male and female fish during four reproductive phase of the cycle.

The four phases of the one year cycle in which gonadal state observed are

1. Preparatory phase (January to March).
2. Pre spawning phase (April to July).
3. Spawning phase (August to October)
4. Post spawning phase (November to December).

The conditions of the gonads are at the developing stage while in the pre spawning phase, the gonads are at the different stages of maturity comprising of maturing and mature stages. In spawning phases the gonads are ripe and some are in the spent stages and post spawning phases includes immature stage.

OBSERVATION

Seasonal Ovarian Cycle:

The morphological and histological changes in the ovary indicate that the fish *N. notopterus* passed through different phases of breeding cycle as explained below.

a) Preparatory Phase:

- i. **Histology of Ovary:** In preparatory phase the histological section of the ovary is characterized by the presence of large number of oocytes belonging to early and late perinucleolus stages (Fig.1).
- ii. **Changes in the histology of ovary after exposure to Profenofos:** in preparatory phase the histology of ovary the vitellogenesis is not seen in young follicles (Fig. 5).

b) Pre spawning phase:

- i. **Histology of Ovary:** In the pre spawning phase the histology is characterizes by the presence of all stages of oocytes with large number of oocytes belonging to vitellogenic group. In this phase of reproductive cycle ovary shows the transformation of oocytes from primary yolk globule stage to secondary yolk globule and to tertiary yolk globule stage and the presence of very few migratory nucleolus stage oocytes was observed (Fig. 2).
- ii. **Changes in the histology of ovary after exposure to Profenofos:** In pre spawning phase the histological section of the ovary after Profenofos exposure shows atretic follicles and vitellogenic follicles are not under the process of vitellogenesis. Although these oocytes were visible they exhibit poor staining (Fig. 6).

c) Spawning Phase:

- i. **Histology of Ovary:** In spawning phase the histology of ovary shows increased number of migratory nucleolus stage oocytes indicating final stage of maturation the breakdown of germinal vesicle takes place (Fig. 3).
- ii. **Changes in the histology of ovary after exposure to Profenofos:** In spawning phase the histology of ovary shows oocytes which are remained inside the

ovary. Some of the vitellogenic oocytes are under the process of degeneration as compared to normal vitellogenic oocytes (Fig. 7).

d) Post spawning Phase:

- i. **Histology of Ovary:** In the post spawning phase the histology of ovary consisting oogonium, chromatin nucleolus and perinucleolus stage of oocytes and the ovary can be categorized as immature stage (Fig. 4).
- ii. **Changes in the histology of ovary after exposure to Profenofos:** In post spawning phase the histology of ovary after exposure to Profenofos shows vitellogenic oocytes have undergone degeneration (Fig. 8).

4. DISCUSSION

The exposure of pesticide causes significant reproductive impairment in terms of specific damage to ovarian tissue. In the present investigation histological examination revealed that under sublethal concentration of profenofos (Curacron 50% EC) to the freshwater fish *N. notopterus* shows pathological symptoms such as increase in the number of atretic follicles that showed an increasing trend with increase in concentration as well as time. Growth of previtellogenic oocytes, large number of atretic follicles noticeable changes were shrinkage in follicles, vacuolation in the stroma, reduction in the number of oocytes, retarded growth of vitellogenic oocytes. Many authors put forward effect of pesticide on ovary. According to Hazarika and Das [9] toxicological impact of BHC

on ovary of air breathing cat fish *Heteropneustus fossilis* showed many structural changes in the ovary of fish during 1 ppm, 5 ppm and 10 ppm BHC dose which alter normal ovarian structure of the fish.

In the present study Profenofos (Curacron) affected normal structure of ovary and gives an idea about various structure and degenerative changes. Similar observation was made by Kulshrestha and Arora [10]. According to Magar and Biase [11] in acute exposure (for 4 days) reduction in size of mature oocytes, vacuolation in cytoplasm and disruption were reported, were as, in chronic exposure (for 15 days) complete loss of normal configuration of ovary, elongated ovarian follicles, necrosis and abnormal shaped fragmented ova were reported.

The most striking effect of Profenofos (Curacron 50% EC) observed under present investigation is the disappearance of mature oocytes during mature stages whereas, at ripening stage, several oocytes were observed to be in the process of atresia [12] however few degenerating oocytes were presented along with remaining mature oocytes and had a distort appearance [13].

In the present study the most notable changes that appeared in the pesticide treated ovaries were increased number of follicular atresia, improper incorporation of yolky materials in mature oocytes and reduction in the number of SGP oocytes. Occurrence of atretic follicles is a common phenomenon in amphibian ovaries [14]. But their presence in enormous numbers is reported to be a histopathological response to toxicants [15].

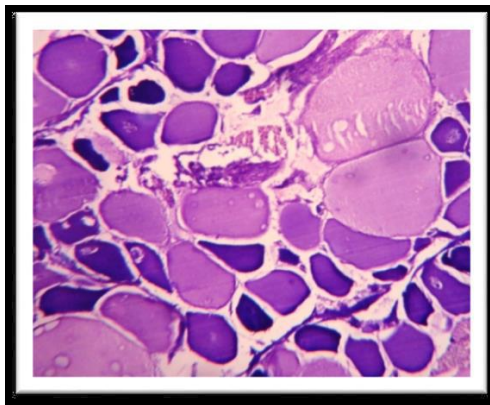


Fig. 1. Microphotograph of part of control ovary of the fish *N. notopterus* during preparatory phase of reproductive cycle

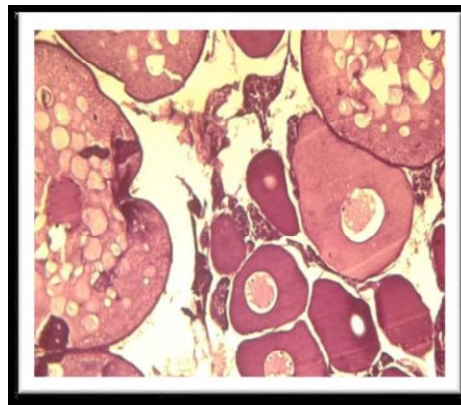


Fig. 2. Microphotograph of part of control ovary of the fish *N. notopterus* during pre-spawning phase of reproductive cycle

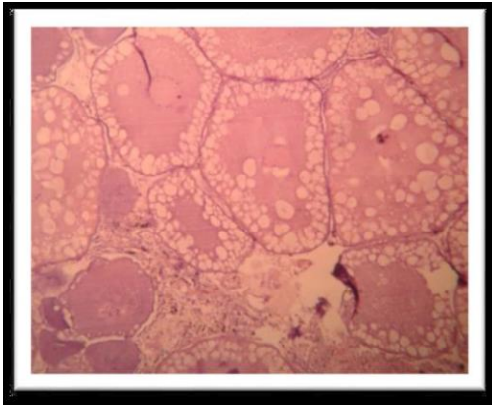


Fig. 3. Microphotograph of part of control ovary of the fish *N. notopterus* during spawning phase of reproductive cycle.

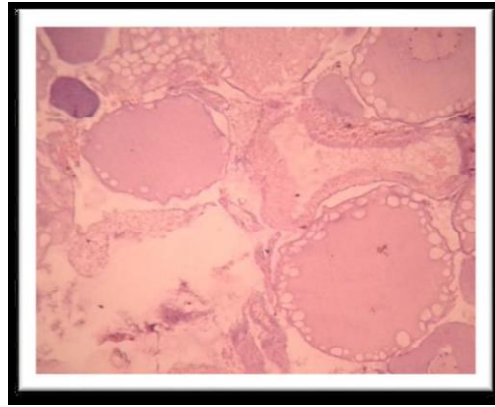


Fig. 4. Microphotograph of part of control ovary of the fish *N. notopterus* during post-spawning phase of reproductive cycle.

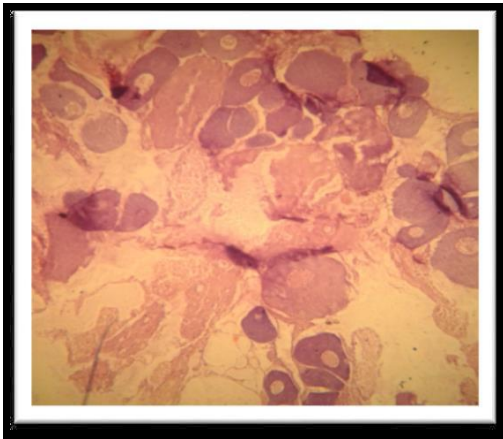


Fig. 5. Microphotograph of part of exposed ovary of the fish *N. notopterus* to sublethal concentration of profenofos during preparatory phase of reproductive cycle

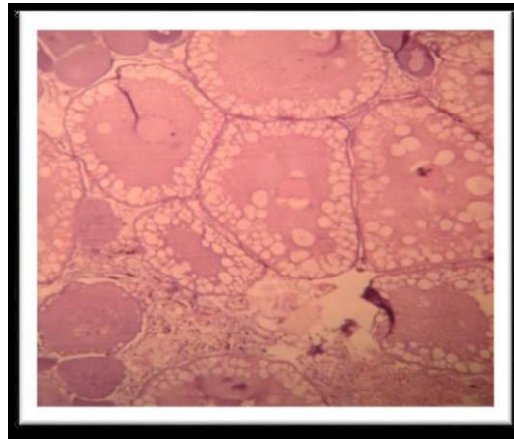


Fig. 6. Microphotograph of part of exposed ovary of the fish *N. notopterus* to sublethal concentration of profenofos during pre-spawning phase of reproductive cycle

Lal and Singh [16] opined that pesticides interfere with the production of free cholesterol, the sex hormone precursor, and hence reduced steroid production. A significant reduction in testosterone and 11-ketotestosterone in male and testosterone and estradiol-17 β in female. Anamika and Mishra [17] assess the histopathological impact of lethal (0.3 ppm) and sub lethal (0.06 ppm) concentrations of profenofos in the ovary of an air breathing fresh water teleost *Channa gachua*. Reduced size of mature oocytes, vacuolation in cytoplasm, damaged ovarian follicles, increase in inter-follicular space, breaking of ovarian wall, occurrence of necrosis, damaged structure of ovarian follicles, formation of fragmented ova,

atretic oocytes and extrusion of karyoplasms was observed in mature oocytes.

The present study revealed, that Profenofos (Curacron) 50% EC seriously impair the gonadal maturation in the fresh water fish *N. notopterus* thereby affecting the normal ova production due to increasing tendency to atresia. It can be suggested that Profenofos (Curacron) might interfere with the gonadotrophic hormone secretion in the hypothalamo-hypophyseal system which result in the decreased ovarian activity during the reproductive programming of gonads also suggested by Mohan [18], Sharma and Verma [19].

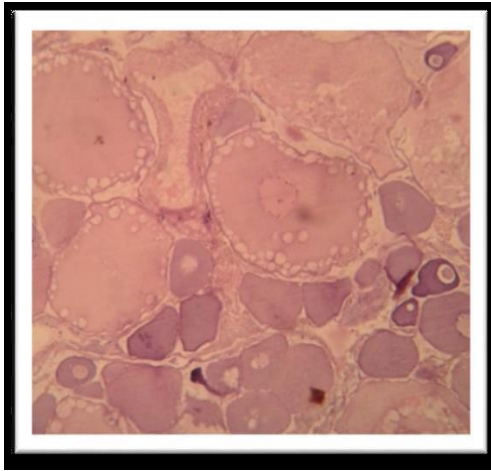


Fig. 7. Microphotograph of part of exposed ovary of the fish *N. notopterus* to sublethal concentration of profenofos during spawning phase of reproductive cycle

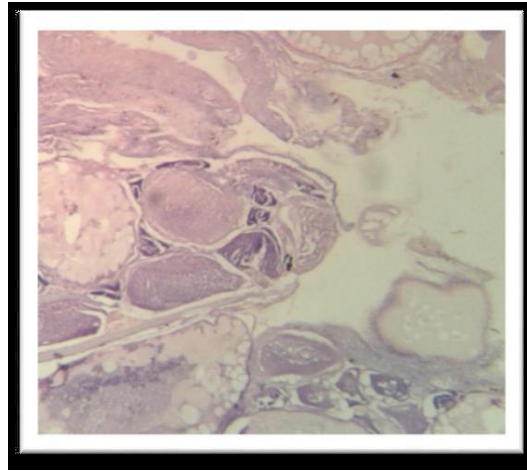


Fig. 8. Microphotograph of part of exposed ovary of the fish *N. notopterus* to sublethal concentration of profenofos during post-spawning phase of reproductive cycle

5. CONCLUSION

From the present study it is concluded that the sublethal exposure of Profenofos (Curacron 50% EC) to the freshwater fish *N. notopterus* resulted in marked degenerative changes in the ovary and found the degeneration of follicular walls, connective tissue and ultimately it effects the reproductive mechanism of the fish and its population. These results also indicate that even low concentration of profenofos have a toxic effects on fishes. Therefore these pesticides should be used with great caution and in a sustainable way so that it may not be hazardous to aquatic biota and human beings.

COMPETING INTERESTS

Authors have declared that no competing interests exist.

REFERENCES

1. Belazutshi, Raghuprasad SG. Impact of pollution on fresh and marine water resources. *J Poll Res.* 2008;27:461-466.
2. Fiumann LA. Water quality and early life stages of fishes. *American Fisheries Society Symposium.* 1993;14:172.
3. Pandey AC, Pandey AK, Das P. Fish and fisheries in relation to aquatic pollution in: *Environmental Issues and Management.* Nature Conservators, Muzaffarnagar. 2000;87-112.
4. Kime DE. The effects of pollution on reproduction in fish. *Review fish Biology and Fisheries.* 1995;3:52-96.
5. Moustafa GG, Shaaban F, Hadeed AA, Elhady WM. Immunotoxicological, biochemical, and histopathological studies on Roundup and Stomp herbicides in Nile catfish (*Clarias gariepinus*). *Veterinary World.* 2016;9(6):638.
6. Bantu N, Hagos Z, Krishna C, Krishnan G, Vakita R, Karimasetty S, Bantu NK. Impact of profenofos and carbosulfan on dehydrogenase activity of freshwater fish, *Labeo rohita* (Hamilton). *J. Biol. Today's World.* 2017;6(1):9-20.
7. Malhotra SK. Ecological ecthyo-parasitology in India. *Indian Rev Life Sci.* 1989;9:253-296.
8. Zhang C, Hu R, Huang J, Huang X, Shi G, Li Y, et al. Health effect of agricultural pesticide use in China: Implications for the development of GM crops. *Scientific Reports.* 2016;6.
9. Hazarika R, Das M. Toxicological impact of BHC on the ovary of the air-breathing catfish *Heteropnueutes fossilis* (Bloch). *Bulletin of Environmental Contamination and Toxicology.* 1998;60(1):16-21.
10. Kulshrestha SK, Arora N. Impairments induced by sublethal doses of two pesticides in the ovaries of a fresh water teleost *Channa striatus* (Bloch). *Toxicology Letters.* 1984;20(1):93-98.
11. Magar RS, Biase UE. Histopathological impact of malathion on the ovary of the

- freshwater fish *Channa punctatus*. International Journal of Environmental Science. 2013;2(3):59-61.
12. Saxena OP, Parashari A, Yadav RS. Toxicity of few heavy metals to freshwater fish *Channa punctatus*. Journal of Ichthyology. 1981;1:37-40.
 13. Shukla JP, Pandey K. Impaired ovarian function in arsenic treated freshwater fish *Colisa fasciatus* (Bl and Sch). Toxicology Letters. 1984;20:5-8.
 14. Saidapur SK, Pramoda S, Pancharatna M. The occurrence of fibrous atretic follicles in the ovaries of *Rana cyanophlyctis* and *Rana tigerina*. Current Science. (1982): 51(21):1043-1044.
 15. George S, Andrews MI. Toxic effects of endosulfan on histology of gonad in the green frog *Rana hexadactyla* Lesson. Proceedings of the sixth Kerala Science Congress. 1994;69-70.
 16. Lal B, Singh TP. Impact of pesticide on lipid metabolism in the freshwater catfish *Clarias batrachus* during the vitellogenic phase of its annual reproductive cycle. Ecotoxicology and Environmental Safety. 1987;13:13-23.
 17. Anamika Ranjana, Mishra AP. Histopathological alterations of profenofos on the ovary of the freshwater air-breathing fish *Channa guchua*. The Asian Journal of Animal Science. 2015;10(1):8-13.
 18. Mohan RM. Malathion induced changes in the ovary of freshwater fish *Glossogobins giuris* (Ham). Pollution Research. 2000; 19(1):73-75.
 19. Sharma Y, Verma V. Histopathological effects of tannery effluents in the testis of commercial carp *Cirrhinus mrigala* (Ham). Biochemical Cell Archives. 2001b;1:93-101.

© 2018 Tazeen and Kulkarni; This is an Open Access article distributed under the terms of the Creative Commons Attribution License (<http://creativecommons.org/licenses/by/4.0>), which permits unrestricted use, distribution, and reproduction in any medium, provided the original work is properly cited.

Peer-review history:
The peer review history for this paper can be accessed here:
<http://www.sciencedomain.org/review-history/27969>