



Prophylactic and Curative Effects of Thymoquinone against CCL₄-Induced Hepatotoxicity in Rats

H. Khither^{1*}, W. Sobhi¹, A. Mosbah¹ and M. Benboubetra¹

¹Laboratory of Applied Biochemistry, Faculty of Nature and Life Sciences, Ferhat Abbas Setif 1 University, Setif 19000, Algeria.

Authors' contributions

This study was carried out in collaboration between all authors. Author MB designed the study, performed the statistical analysis, wrote the protocol and wrote the first draft of the manuscript. Authors HK, WS and AM managed the analyses of the study and managed the literature searches. All authors read and approved the final manuscript.

Article Information

DOI: 10.9734/EJMP/2018/38830

Editor(s):

(1) Prem K. Ramasamy, Department of Biochemistry, Brandeis University, Waltham, MA, USA.
(2) Marcello Iriti, Professor, Plant Biology and Pathology, Department of Agricultural and Environmental Sciences, Milan State University, Italy.

Reviewers:

(1) Ioana Stanciu, University of Bucharest, Romania.
(2) G. Bupesh, Bharath Institute of Higher Education & Research, India.
Complete Peer review History: <http://www.sciencedomain.org/review-history/22696>

Original Research Article

Received 28th October 2017
Accepted 5th January 2018
Published 11th January 2018

ABSTRACT

Background: Natural products from medicinal plants such as thymoquinone (TQ), the major compound derived from *Nigella sativa* L. Which has received considerable attention in recent years due to its diverse pharmacological properties, including antioxidant and anti-inflammatory activities? The aim of this study is the investigation of prophylactic and curative effects of TQ against carbon tetrachloride (CCl₄)-induced hepatotoxicity in male albino rats.

Materials and Methods: Hepatotoxicity was induced in rats by intraperitoneal administration of 3 ml/kg, 1:1 (V/V) mixture of CCl₄ and olive oil both before and after treatment for 7 days with TQ. Prophylactic and curative effects of TQ were evaluated by estimating the activities of alanine aminotransferase (ALT), aspartate aminotransferase (AST) and alkaline phosphatase (ALP).

Results: CCl₄ administering by intraperitoneal injection led to significant (P<0.05) increase in serum transaminases (ALT and AST) and phosphatase (ALP) respectively compared with control animals. Thymoquinone showed significant (p<0.05) hepatoprotective activity by decreasing the activities of ALT, AST, ALP in both prophylactic and curative effects. These results revealed that thymoquinone possesses significant hepatoprotective and hepatocurative effects against

*Corresponding author: E-mail: h.khither@yahoo.fr;

CCl₄-induced toxicity via its antioxidant and anti-inflammatory activities but the hepatocurative effect was the most effective.

Conclusion: Thymoquinone is a compound known for its pharmacological proprieties. We illustrated in this work, its important effect against hepatotoxicity induced by a toxic agent as CCL₄ when it's administrated in prophylactic or curative way.

Keywords: *Thymoquinone; carbon tetrachloride; hepatotoxicity; prophylactic effect; curative effect; hepatic markers.*

1. INTRODUCTION

Thymoquinone (TQ) is the major active compound derived from the medicinal *Nigella sativa* [1]. It is a member of bioflavonoid with antioxidant, anti-inflammatory, antidiabetic, neuroprotective, and anti-arthritic properties [2,3,4,5,6]. Hepatotoxicity induced by carbon tetrachloride (CCl₄), is widely used for modeling liver injury in rats [7]. Because it is the principal site for CCl₄ biotransformation, the hepatotoxicity of CCl₄ is the result of cytochrome P-450-dependent reductive dehalogenation to form a highly reactive trichloromethyl free radical, CCl₃[•] [8]. The aim of this research was to evaluate the *in vivo* effects of TQ and to investigate its prophylactic and curative effects on hepatotoxicity induced by CCL₄.

2. MATERIALS AND METHODS

2.1 Chemicals

Thymoquinone, carbon tetrachloride (CCL₄) and formaldehyde were purchased from Sigma Aldrich.

2.2 Experimental Animals

Fifty-six male Wistar albino rats (200–250 g) were purchased from the Animal House of Pastor institute Alger, Algeria. The animals were acclimatized for one week and maintained under standard conditions of temperature (22 ± 2°C), and 12 hours light/dark cycle. The rats were fed with a standard diet and water.

2.3 Induction of Hepatotoxicity

The induction of hepatotoxicity was based on the procedure described by Wang et al. [9] with slight modification, the albino rats were randomly divided into eight treatment groups of seven rats per group as follows:

Group I (normal control): received physiological water (3 ml/kg).

Group II received physiological water with 0.1% of tween80.

Group III received physiological water (3 ml/kg). On the seventh day, animals were administered olive oil (3 ml/kg).

Group IV received physiological water (3ml/kg). On the seventh day, animals were injected with a fresh mixture of CCl₄, and olive oil (3 ml/kg, V:V).

To evaluate the potent hepato-protector effect of thymoquinone, we have designed the following experimental scheme:

2.3.1 Prophylactic effect

Group V pre-treated with TQ at a dose of [2.5 mg/kg/day] dissolved in 0.1% of tween80.

Group VI pre-treated with TQ at a dose of [05 mg/kg/day] dissolved in 0.1% of tween80.

On the seventh day, animals were injected with a fresh mixture of CCl₄, and olive oil (3 ml/kg, V: V), half an hour after the administration of the last dose of the pre-treatment TQ.

2.3.2 Curative effect

On the first day, animals were injected with a fresh mixture of CCL₄, half an hour before the administration of the first dose of TQ.

Group VII treated with TQ at a dose of [2.5 mg/kg/day] dissolved in 0.1% of tween80.

Group VIII treated with TQ at a dose of [05 mg/kg/day] dissolved in 0.1% of tween80.

All the treatments were administered by oral gavage for 7 days. After 24 hours, the animals were sacrificed under diethyl ether anesthesia by cervical dislocation. Blood samples were collected from the retro-orbital sinus of the eye by ocular puncture into heparinized tubes for biochemical analyses. Serum was separated by

centrifugation at 3,000 rpm for 10 min., at 4°C. Rat livers were quickly excised and perfused with chilled 1.15% (w/v) KCl solution in order to remove all traces of haemoglobin. The livers were blotted dry, weighed and a portion was used to prepare homogenate and stored at -80°C pending analysis while the remaining parts were preserved in 10% formalin saline for histopathological analysis.

2.4 Assay of Liver Marker Enzymes

Liver enzymes- alanine, and aspartate aminotransferases (ALT and AST), and alkaline phosphatase (ALP), were assayed using sprinreact diagnostic kits with a Bechman auto analyzer at the biochemistry laboratory of Setif anti-cancer centre, Algeria. Hepatoprotective activity of TQ was calculated according to the formula of Singh et al. [10].

$$\text{Hepatoprotective activity (\%)} = 1 - \frac{[TC - N]}{[C - N]} \times 100$$

Where TC, C, and N are the measurable variables in rats treated with TQ plus CCl₄, CCl₄, and normal animals respectively.

2.5 Histopathological Examination

Livers of rats from different groups perfused with 10% neutral formalin solution were dehydrated and embedded in paraffin. Paraffin sections were made and stained using hematoxylin-eosin [11]. The stained sections were examined under a microscope for histopathological changes in liver architecture, and their photomicrographs were carried out in the pathology laboratory of Setif University Hospital. Algeria.

2.6 Statistical Analysis

The data obtained were analyzed using one-way analysis of variance (ANOVA), followed by Tukey's test for all parameters and expressed as mean ± SEM. The p-value < 0.05 was considered statistically significant.

3. RESULTS

3.1 Biomarkers of Liver Function

The effects of pre-treatment with TQ on serum AST, ALT and ALP activities in CCl₄-intoxicated rats are shown in Table 1. Intoxication of rats

with CCl₄ caused hepato-cellular damage as shown by significant elevation (p < 0.05), in the activities of serum AST (16, 42 times / 1542.20%), ALT (22.87 Times / 2187.69%), and ALP (1.70 times / 69.84%), compared to control. However, pre-treatment of rats with TQ for 7 days (at both 2.5 mg and 05 mg/kg b. wt), protected the rats against CCl₄-induced hepato-toxicity by reductions in the activities of the hepatic enzymes in the serum. Pre-treatment with 2.5 mg / kg b. wt. of TQ decreased AST, ALT and ALP activities by 89.94%, 87.80% and 23.08%, respectively. Similarly, pre-treatment of rats with 05 mg/ kg b. wt. of TQ decreased these enzymes by 91.39%, 89.31% and 27.06%, respectively. Thus, the hepatoprotective effect percentage (%) of both Pre-treatments with 2.5 and 05 mg/ kg b. wt were illustrated in Table 2.

While, treatment of rats with TQ for 7 days (at both 2.5 mg and 05 mg /kg b. wt), treated the rats against CCl₄-induced hepato-toxicity by significant reductions in the activities of the hepatic enzymes in the serum. Treatment with 2.5 mg / kg b. wt. of TQ decreased AST, ALT and ALP activities by 94.77%, 97.19% and 25.23%, respectively. Similarly, treatment of rats with 05 mg/ kg b. wt. of TQ decreased these enzymes by 94.86%, 98.27% and 37.38%, respectively. Thus, the hepatocurative effect percentage (%) of both treatments with 2.5 and 5 mg/ kg b. wt were illustrated in Table 2.

3.2 Histopathology

The photomicrographs obtained from the histopathological examination are depicted in Fig. 1. Liver sections from normal control rats revealed normal architecture. Livers of CCl₄-treated rats showed abnormal architecture with severe congestion, extensive necrosis of hepatocytes, oedema, areas of fatty change (steatosis) and diffuse inflammatory cells infiltration including mononuclear, polynuclear and histiocyte. Pre-treatment with 2.5 mg and 5 mg/kg reduced the severity of hepatic damage as shown by the mild and few inflammatory cells infiltration with less necrosis and fewer cells infiltration, respectively. While, Treatment with 2,5mg and 5 mg/kg showed nearly normal architecture of liver tissue back to the elimination of all hepatic damage except only less congestion with treatment by 2.5 mg/kg.

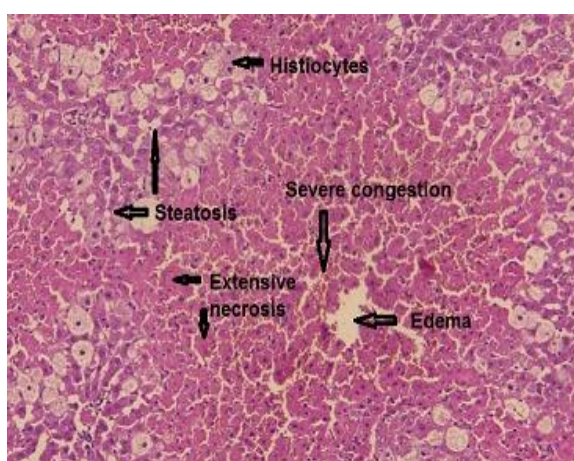
Table 1. Serum levels of liver enzymes following different treatments (n=7)

Treatment (mg/kg)	AST (U/L)	ALT (U/L)	ALP (U/L)
Control	109.00 ± 7.94 ***	57.7 ± 6.12***	126 ± 4.00
TQ (2.5 mg /kg) + CCl ₄	180,00 ± 33.4***	161 ± 25.3***	164.6 ± 3.70
TQ (5 mg/kg) + CCl ₄	154,00 ± 13.1***	141 ± 31.3***	156.1± 17.50
CCl ₄ + TQ (2.5 mg/kg)	93.60 ± 7.30 ***	37.1 ± 2.84***	160 ± 11.3
CCl ₄ + TQ (5 mg/kg)	92.00 ± 5.04 ***	22.9 ± 9.34***	134 ± 15.1
CCl ₄ Only	1790 ± 97.1	1320 ± 93.7	214 ± 27.7

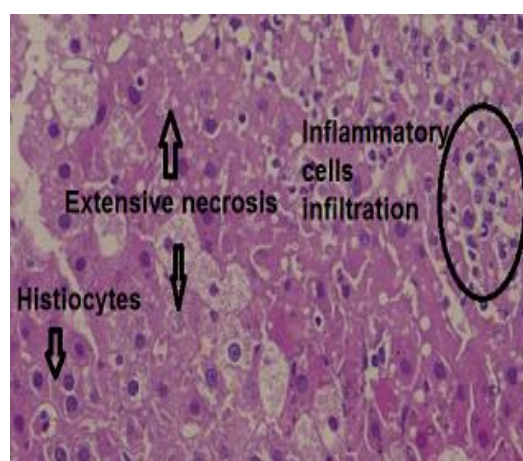
Values are expressed as means ± SEM (n =7).

* Significant difference (*: p ≤ 0 .05, **: p ≤ 0 .01, ***: p ≤ 0.001) against CCL₄ treated group.

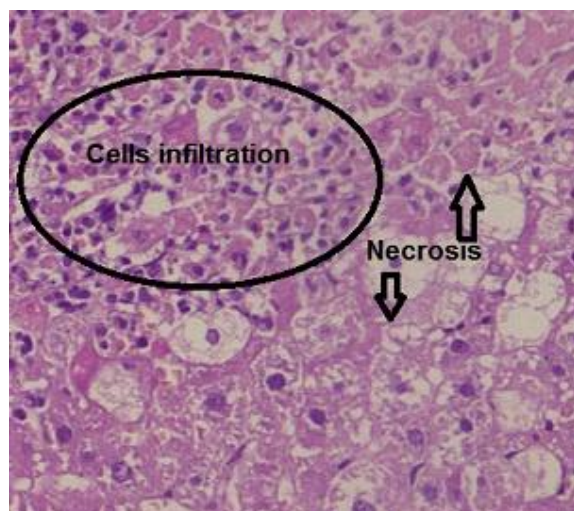
Experiments were performed three times and analysis for each experiment was carried out in triplicates



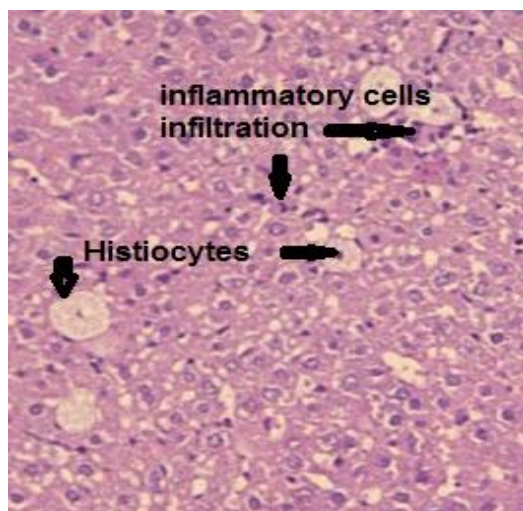
(A)



(B)



(C)



(D)

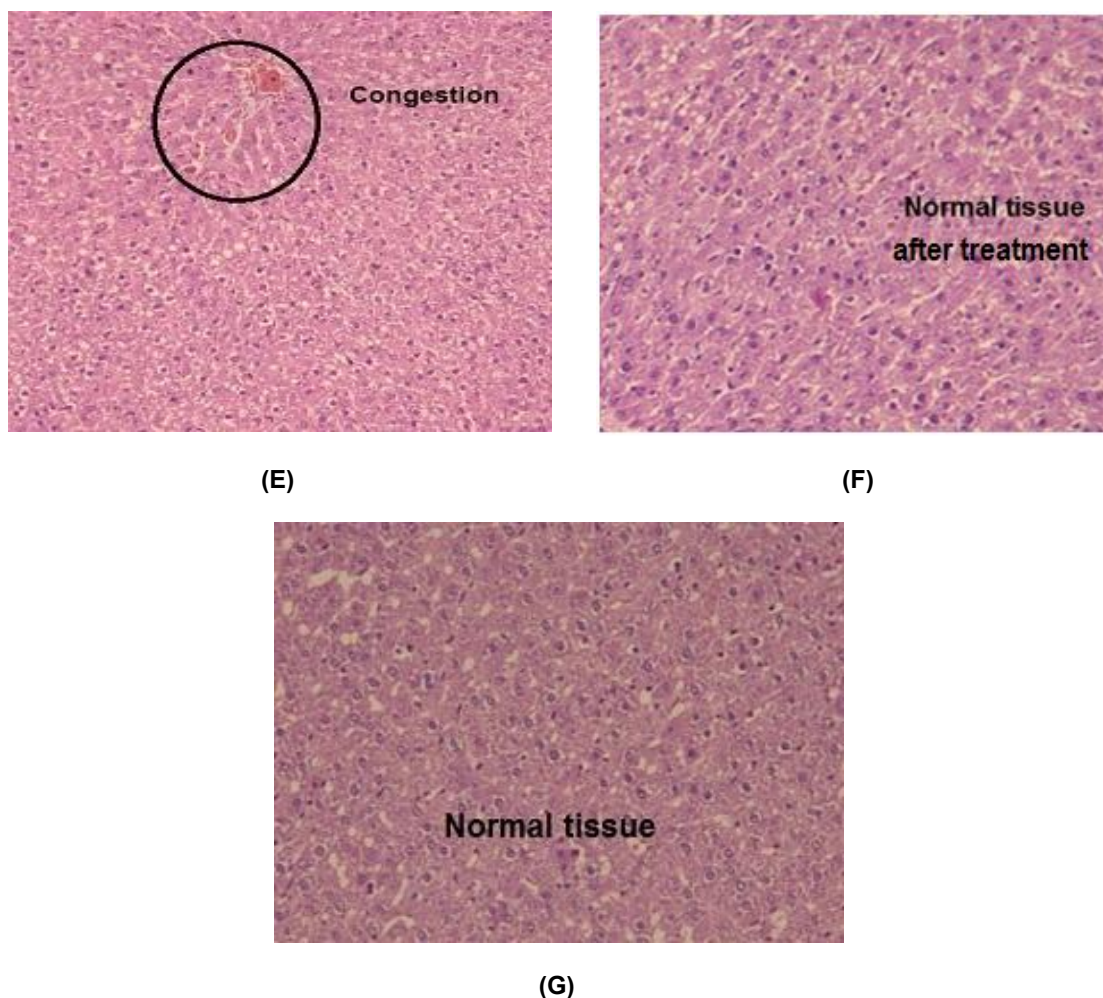


Fig. 1. Photomicrographs of the liver tissue from rats treated with TQ x 100

A: (CCL₄ Only): Severe congestion, extensive necrosis, oedema, B: (CCL₄ Only) severe mononuclear, histiocyte and polynuclear infiltration. C: (2.5 mg/kg TQ + CCL₄): Necrosis and inflammatory cells infiltration. D: (2.5 mg/kg TQ + CCL₄): Less mononuclear and histiocytes infiltration E: (CCL₄+ 2.5 mg/kg TQ): Less congestion. F: (CCL₄ + 5 mg/kg TQ): Normal tissue. G: (Control): Normal liver architecture

Table 2. Hepatoprotective and hepatocurative activities of TQ against CCl₄-induced toxicity in rats

% Treatment	Liver function indicator	AST	ALT	ALP
Hepatocurative	CCl ₄ + TQ (2.5 mg/kg)	100.92	101.63	61.36
	CCl ₄ + TQ (5 mg/kg)	101.01	102.76	90.91
Hepatoprotective	TQ (2.5 mg/kg) + CCl ₄	95.78	91.82	56.14
	TQ (5 mg/kg) + CCl ₄	97.32	93.40	65.80

TQ + CCl₄: Hepatoprotective effect % and CCl₄ + TQ: Hepatocurative effect %

4. DISCUSSION

CCl₄ induced liver injury in rats by its biotransformation by cytochrome P450 system to highly reactive trichloromethyl free radicals (CCl₃[•]), which reacted rapidly with molecular

oxygen to produce the trichloromethyl peroxy (CCl₃O₂[•]). This highly toxic radical is responsible for attacks on unsaturated fatty acids of phospholipids present in the cell membrane, leading to lipid peroxidation in the liver cells, disrupts Ca²⁺ homeostasis, and eventually kills

cells [12,13], which, initiated liver cell destruction [14], increased plasma levels of hepatic enzymes (AST, ALT and ALP). These enzymes are released into the circulation following to cellular breakdown.

This study is the first one to determine hepatoprotective together with hepatocurative effects of TQ against CCL₄ toxicity. The previous experimental studies have shown that treatment with CCl₄ led to an increase in serum levels of AST, ALT and ALP [15,16,17,18]. The hepatotoxicity of CCl₄ was confirmed in our study by significant increases of serum levels of AST, ALT and ALP by 16, 42 times, 22.87 times and 1.70 times, respectively.

After treatment of rats with TQ the results showed significant decreases in activities of the liver enzymes in both prophylactic and curative effects, hepatocurative effect was the most effective because it decreased the enzymes to levels approaching the normal values. This is an indication of the stabilization of the plasma membrane and the repair of hepatic tissue damage caused by CCl₄. Thus, The hepatocurative effect with 5 mg/ kg b. wt of TQ was the most effective among the doses used.

The histopathological assessment revealed significant histological changes in the liver tissue of rats treated with CCL₄-induced liver lesions such as fatty degeneration (steatosis i.e. accumulation of triglycerides in the liver), oedema and necrosis [19]. Our findings were consistent with previous reports on CCL₄ induced hepatotoxicity. However, histological section of the liver tissue of rats pretreated with TQ showed moderate improvement of the liver lesions compared to the CCL₄ treated group suggesting the moderate hepato-protective effect of TQ. While, treatment with TQ led to marked structural improvement approaching the normal architecture of the liver damage compared to the CCL₄ treated group suggesting its significant hepato-curative effect.

Thus, quantitative measurements of plasma levels of liver enzymes, together with a histopathological examination of hepatocytes provide a good assessment of the extent of liver damage or regeneration when TQ challenged with CCl₄. We suggest that the reason behind this is the antioxidant and anti-inflammatory activities of TQ, which blocked at least partly, the effect of released free radicals by CCl₄ which led to lipid peroxidation and hence membrane

destabilization and eventually liver cell injury by its significant upregulation of antioxidant Systems [20], superoxide scavenging and anti-lipid peroxidation [21,22], in part, and eicosanoid generation, namely thromboxane B2 and leucotriene B4. Therefore, the effect of thymoquinone on thromboxane B2 generation could be a contributing factor to its possible hepatoprotective and hepatocurative effects [22,23].

5. CONCLUSION

The present study demonstrated that TQ had an excellent curative effect against hepatotoxicity induced by CCL₄ with an important prophylactic effect. Both prophylactic and curative effects of thymoquinone may be explained by its antioxidant and anti-inflammatory properties which were well documented in several studies.

CONSENT

It is not applicable.

ETHICAL APPROVAL

This study was carried out in strict accordance with the recommendations in the Guide for the Care and Use of Laboratory Animals of the National Institutes of Public Health of Algeria (INSP). The protocol was approved by the Committee on the Ethics of Animal Experiments of the University of Ferhat Abbas–Setif 1.

ACKNOWLEDGEMENTS

The authors would like to acknowledge the University of Setif 1. Research was performed in the Laboratory of Applied Biochemistry, Faculty of Nature and Life Sciences, University of Setif 1, Setif 19000, Algeria.

COMPETING INTERESTS

Authors have declared that no competing interests exist.

REFERENCES

1. Solati Z, Baharin BS, Bagheri H. Antioxidant property, thymoquinone content and chemical characteristics of different extracts from *Nigella sativa* L. Seeds. Journal of the American Oil Chemists' Society. 2014;91(2):295–300.

2. Inci M, Davarci M, Inci M, Motor S, Yalcinkaya FR, Nacar E, et al. Anti-inflammatory and antioxidant activity of thymoquinone in a rat model of acute bacterial prostatitis. *Human & Experimental Toxicology*. 2013;32(4):354-361.
3. Badr G, Alwasel S, Ebaid H, Mohany M, Alhazza I. Perinatal supplementation with thymoquinone improves diabetic complications and T cell immune responses in rat offspring, *Cell. Immunology*. 2011;267:133–140.
4. Kanter M. Protective effects of thymoquinone on the neuronal injury in frontal cortex after chronic toluene exposure. *Journal of Molecular Histology*. 2010;42:39–46.
5. Budancamanak M, Kanter M, Demirel A, Ocakci A, Uysal H, Karakaya C. Protective effects of thymoquinone and methotrexate on the renal injury in collagen-induced arthritis. *Archives of Toxicology*. 2006;80: 768–776.
6. Tekeoglu I, Dogan A, Ediz L, Budancamanak M, Demirel A. Effects of thymoquinone (volatile oil of black cumin) on rheumatoid arthritis in rat models. *Phytotherapy Research*. 2007;21:895–897.
7. Chopra P, Roy S, Ramalingaswami V, Nayak NC. Mechanism of carbon tetrachloride hepatotoxicity. An *in vivo* study of its molecular basis in rats and monkeys. *Laboratory Investigation*. 1972; 26:716-727.
8. McCay PB, Lai EK, Poyer JL, DuBose CM, Janzen EG. Oxygen and carbon-centred free radical formation during carbon tetrachloride metabolism. *Journal of Biological Chemistry*. 1984;259:2135-2143.
9. Wang BJ, Liu CT, Tseng CY, Wu CP, Yu ZR. Hepatoprotective and antioxidant effects of Bupleurum kaioi Liu (Chao et Chuang) extract and its fractions fractionated using supercritical CO₂ on CCl₄-induced liver damage. *Food and Chemical Toxicology*. 2004;42:609-617.
10. Singh B, Saxena AK, Chandan BK, Anand KK. Hepatoprotective activity of verbenaol on experimental liver damage in rodents. *Fitoterapia*. 1998;69:135-140.
11. Bancroft JD, Gamble M. Theory and practice of histological techniques. 5. Ed. Edinburgh. Churchill Livingstone. 2002; 172-5:593-620.
12. Recknagel RO, Glende, EAJ, Dolak JA, Waller AR. Mechanism of carbon tetrachloride toxicity. *Pharmacology & Therapeutics*. 1989;43:139-154.
13. Weber LW, Boll M, Stampfl A. Hepatotoxicity and mechanism of action of haloalkanes: Carbon tetrachloride as a toxicological model. *Critical Reviews in Toxicology*. 2003;33:105-136.
14. Jaeschke H. Reactive oxygen and mechanisms of inflammatory liver injury: Present concepts. *Journal of Gastroenterology and Hepatology*. 2011; 26(1):173-179.
15. AL-Shabanah OA, Alam K, Nagi MN, Alrikabi AC, Al-Bekairi AM. Protective effect of aminoguanidine, a nitric oxide synthase inhibitor, against carbon tetrachloride induced hepatotoxicity in mice. *Life Science*. 2000;66:265-270.
16. Brai BIC, Adisa RA, Odetola A A. (2014). Hepatoprotective properties of aqueous leaf extract of persea americana, mill (lauraceae) 'avocado' against CCL₄-induced damage in rats. *African Journal of Traditional Complementary and Alternative Medicine*. 2014;11(2):237-244.
17. Naziroglu M, Cay M, Ustundag B, Aksakal M, Yekeler H. Protective effects of vitamin E on carbon tetrachloride-induced liver damage in rats. *Cell Biochemistry and Function*. 1999;17:253-259.
18. Teocharis SE, Margeli AP, Skaltsas SD, Spiliopoulou CA, Koutselini AS. Induction of methallothionein in the liver of carbon tetrachloride intoxicated rats: An immunohistochemical study. *Toxicology*. 2001;161:129-138.
19. Boll M, Weber LWD, Becker E, Stampfl A. Pathogenesis of carbon tetrachloride-induced hepatocyte injury. Bioactivation of CCl₄ by cytochrome P450 and effect on lipid homeostasis. *Zeitschrift für Naturforschung*. 2001;56c:111-12.
20. Aycan IÖ, Tüfek A, Tokgöz O, Evliyaoglu O, Firat U, Kavak GÖ, et al. Thymoquinone treatment against acetaminophen-induced hepatotoxicity in rats. *International Journal of Surgery*. 2014;12:213 – 218.
21. Nagi MN, Mansour MA. Protective effect of thymoquinone against Doxorubicin-induced cardiotoxicity in rats: A possible Mechanism of protection. *Pharmacological Research*. 2000;41(3):283-289.
22. Houghton PJ, Zarka R, Heras B, Hoult RS. Fixed oil of Nigella sativa and derived

- thymoquinone inhibit eicosanoid generation in leucocytes and membrane lipid peroxidation. *Planta Medica*. 1995;61: 33–36.
23. Khalife KH, Lupidi G, Nagi MN, Alam K, Badary OA, Al-Shabanah OA, et al. Thymoquinone protects against carbon tetrachloride hepatotoxicity in mice via an antioxidant mechanism. *International Journal of Biochemistry and Molecular Biology*. 1999;47:153-159.

© 2018 Khither et al.; This is an Open Access article distributed under the terms of the Creative Commons Attribution License (<http://creativecommons.org/licenses/by/4.0>), which permits unrestricted use, distribution, and reproduction in any medium, provided the original work is properly cited.

Peer-review history:

The peer review history for this paper can be accessed here:
<http://www.sciencedomain.org/review-history/22696>