

Inverted T-Shaped Flap Nursing after the Reverse Double V-Shaped Mastoconstriction Suspension for Breast Cancer

Linfei Liu^{1,2,3}, Lijuan Zhang^{1,2,3*}, Yuanzhen Luo^{1,2,3}, Xuehui Zeng^{1,2,3}, Rong Chen^{1,2,3}

¹State Key Laboratory of Oncology in South China, Guangzhou, China

²Collaborative Innovation Center for Cancer Medicine, Guangzhou, China

³Department of Breast Cancer, Sun Yat-sen University Cancer Center, Guangzhou, China

Email: *zhanglij@susucc.org.cn

How to cite this paper: Liu, L.F., Zhang, L.J., Luo, Y.Z., Zeng, X.H. and Chen, R. (2021) Inverted T-Shaped Flap Nursing after the Reverse Double V-Shaped Mastoconstriction Suspension for Breast Cancer. *Advances in Breast Cancer Research*, 10, 165-172.

<https://doi.org/10.4236/abcr.2021.104014>

Received: August 14, 2021

Accepted: September 12, 2021

Published: September 15, 2021

Copyright © 2021 by author(s) and Scientific Research Publishing Inc. This work is licensed under the Creative Commons Attribution International License (CC BY 4.0).

<http://creativecommons.org/licenses/by/4.0/>



Open Access

Abstract

Objective: To explore the inverted T-shaped flap nursing after breast-conserving surgery combined with the reverse double V-shaped mastoconstriction suspension for breast cancer, and summarizes the nursing methods and experience. **Method:** 5 patients who underwent reverse double V-shaped mastoconstriction suspension and formed inverted T-shaped flap incision were selected from the same medical group in the Department of Breast Cancer of Sun Yat-sen University's Cancer Center from February 1, 2019 to April 30, 2019, and they were evaluated for the recovery of blood supply of skin flap, sensory function of nipple and areola, breast satisfaction, etc. **Results:** Among the 5 patients in this group, the flaps of them all survived smoothly. The one-year follow-up after the operation showed that they were satisfied with the appearance of the breast after the operation, with normal sensory function, and no secondary sagging. **Conclusion:** The most important thing about the inverted T-shaped flap after the reverse double V-shaped mastoconstriction suspension for breast cancer is the blood supply. Close observation of the condition of the skin flap after the operation, strengthening the care of the skin flap, and preventing infection are the keys to the success of the operation.

Keywords

Breast Cancer, Breast Conservation, Mastoconstriction Suspension, Flap Nursing

1. Introduction

Surgery is an important part of the comprehensive treatment of breast cancer.

The traditional treatment will cause breast loss, change the shape, and some patients will suffer self-image disorder, low self-esteem and so on. Some studies have shown that lack of breasts will increase the sense of shame of female patients, affect the life of husband and wife, and then lead to some family problems [1]. Patients who meet the conditions for breast conservation can choose partial mastectomy and tumor resection, remove local lesions, and retain most of the breasts. Breast-sparing surgery not only has fewer traumas, but also preserves the appearance of the breast to the maximum extent, and improves the quality of life and satisfaction of patients after operation [2]. Although breast conservation surgery can retain part of the patient's breast, there are still some problems, such as bilateral breast asymmetry, and large breast sagging after breast conservation surgery. The incision of an inverted T-shaped flap is a common surgical incision with large and prolapsed breasts. The incision of an inverted T-shaped flap can shrink the breast longitudinally and horizontally. The incision of an inverted T-shaped flap can not only remove the lesion, but also achieve the effect of mastoconstriction suspension and obtain the satisfactory appearance of the breast [3]. The treatment of the subcutaneous gland is to remove the excess gland tissue in the reverse double V-shape of the breast and then hang it, and the blood supply of the nipple areola is provided by the basal pedicle of the lower breast and the horizontal double pedicle of both sides of the breast [4] [5]. It reduces the damage to local blood vessels during the operation and facilitates the healing of the wound after the operation. However, most of the glands need to be removed during the operation, which will damage some small arteries and veins, and pull the flap at the incision edge for a long time and a wide range of reasons, which will easily lead to ischemic necrosis of the flap [6] [7] [8]. At present, there are few nursing studies on how to reduce skin flap necrosis after breast reduction and suspension. We summarize 5 successful cases of flap care after inverted V surgery in our department, and share them as follows.

2. Clinical Data

2.1. General Information

The five patients were diagnosed as single breast malignant tumor through preoperative imaging in our hospital from February 1, 2019 to April 30, 2019. The maximum diameter of the mass was 3cm and the distance from nipple areola to nipple areola was more than 2cm, which conformed to the indication of breast conservation. All of them were female aged from 35 to 50 years old, and with large and sagging of bilateral breasts. Partial mastectomy and axillary lymph node dissection were performed on the affected side, mastoconstriction suspension was performed on the contralateral side. There were 2 cases of medial pedicle, 1 case of vertical pedicle, and 2 cases of lateral pedicle.

2.2. Operation Method

Sentinel lymph node biopsy was performed during the operation, and axillary

lymph nodes were dissected if positive. According to the preoperative measurement and positioning, taking the areola as the center, the hypertrophic glandular tissue was removed in the shape of “<and>” on both sides of the nipple areola by the Mckissock method. The nipple areola was vertically double pedicled and moved to the areola area of the new nipple, and the remaining breast skin and glands were properly trimmed and suspended between the second and third rib level at the chest wall, so as to avoid long-term pulling of the cutting edge during the operation, causing edge necrosis. Trimming a small part of the marginal flap pulled for a long time and re-suturing is beneficial to the survival of the flap in the later stage, and also reduces the bloated pedicle tissue that hinders the late rotation [9]. Observe whether the shape of the bilateral breast is symmetrical and whether the blood flow of the nipple areola is normal, eliminate the pressure on the pedicle and stop the bleeding thoroughly to prevent the occurrence of postoperative hematoma. The negative pressure drainage tube was placed on both sides of the incision, and the tension was reduced and sutured by cosmetic method to form an inverted T-shape, and bandaged with appropriate pressure [10].

2.3. Treatment Outcome

The breast volume of 5 patients in this group was basically reduced to the original plan. One patient had fat liquefaction, and the fat liquefaction tissue was removed under local anesthesia. Fifteen days later, the sutures were completely absorbed by themselves and the incision healed, and the rest of the incisions healed in the first stage. The follow-up results within one year showed that the nipple areola decreased from numbness one month after operation to normal sensation, scar hyperplasia was not obvious, and there was no secondary mastoptosis of the breast. Patients' satisfaction with postoperative breast effect and sexual life basically returned to the preoperative level.

3. Nursing

3.1. Preoperative Preparation

Determine the new nipple position (**Figure 1** and **Figure 2**). Methods: The patient took the standing position, selected the clavicle midpoint to the nipple line and extended to the inferior breast wrinkle wall, and the body surface projection from the lower wrinkle wall to the breast midline on the breast surface was regarded as the nipple position reference point 1; took the intersection point of the bilateral upper arm midpoint line and the breast midline as the new nipple position reference point 2, and measured the distances S_n and X_n , which are from the above two reference points to the sternal notch midpoint S and to the inferior xiphoid process midpoint X . Determine the position of the new nipple n , in which the S_n is 19 to 21 cm and the X_n is 9 to 11 cm. Under the guidance of nurses, all the 5 patients in this group cooperated with doctors to locate before operation and keep the mark before operation.

3.2. Postoperative Nursing

3.2.1. Negative Pressure Drainage (Figure 3)

The intraoperative administration of indwelling negative pressure drainage tube according to the surgical area is conducive to promoting wound healing, preventing subcutaneous congestion, increasing the survival rate of flap, reducing the incidence of ischemic infection and necrosis of skin flap after operation [11] [12] [13] [14]. On the day of the operation, the color and drainage volume of the drainage liquid should be observed every hour. If the drainage liquid is more than 100 ml within 1 hour, and the color is bright red, we should be on guard against active bleeding. After that, keep the negative pressure of the drainage

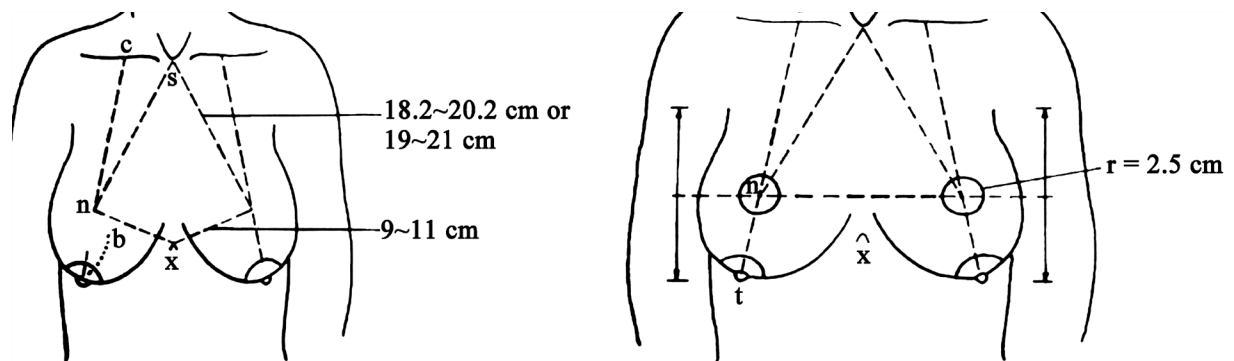


Figure 1. A schematic drawing of the new breast position.

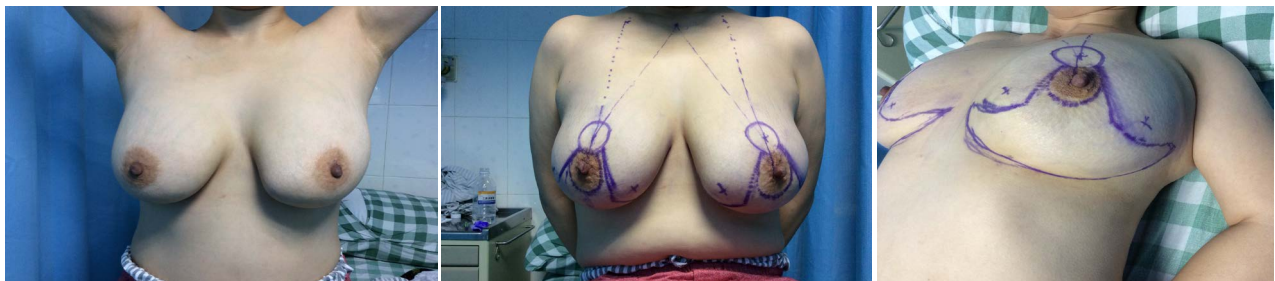


Figure 2. The new position of the nipple before operation.

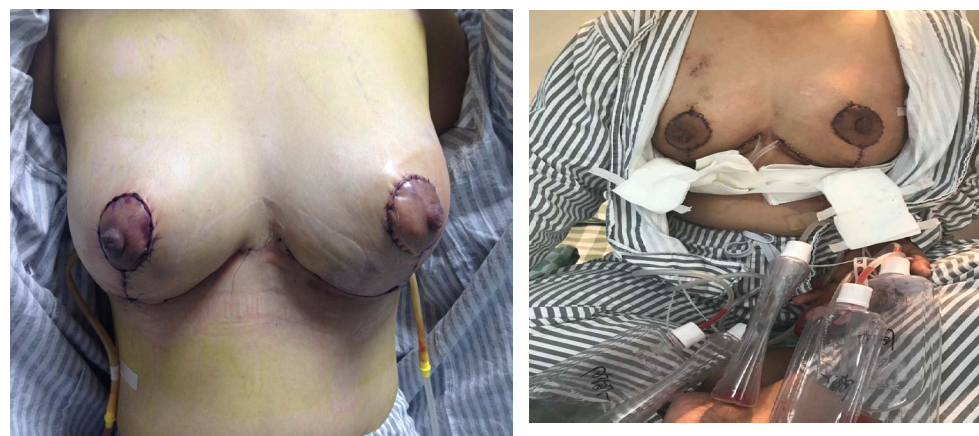

Figure 3. The postoperative renderings.

bottle every day, observe the negative pressure drainage every 2 hours, pump the drainage tube once during each shift, clean up the blood clots, fat and other massive objects in the pipe in time, keep the tube unobstructed and prevent the drainage tube from twisting [15]. If the distension and pain in the operation area is obvious, there is purple ecchymosis under the skin, and there may be subcutaneous effusion or subcutaneous hematoma, so the doctor should be informed immediately. During the operation, according to the surgical incision, 2 to 5 drainage tubes were placed on the chest wall and armpit on the left and right sides.

3.2.2. Application of Unarmed Lymphatic Drainage in Inverted T-Shaped Flap

Part of the lymphatic vessels may be damaged during the operation, resulting in obstruction of reflux [16] and swelling of the arm. After operation, there will be varying degrees of swelling in the incision area and no increase in skin temperature after 3 days, which may also be related to poor lymphatic drainage [17]. Touching can relieve postoperative pain, promote lymphatic reflux and blood flow, which is conducive to the survival of the skin flap. During the growth period of the flap, it can reduce the discomfort such as itching and tingling of the flap, and divert the patient's attention [18]. The newly established blood supply between the skin flap and the chest wall is unstable, and the patient is restless due to wound pain and discomfort, which can easily lead to subcutaneous bleeding and subcutaneous effusion caused by the re-separation of the skin flap attached to the chest wall after operation, thus affecting the blood supply of the flap and causing flap necrosis [19] [20] [21]. Therefore, on the first day after operation, the international lymphoedema therapist used unarmed lymphatic drainage to touch the affected side with sliding strokes, which were pushed from the dorsum of both hands to the supraclavicular lymph nodes. The strength of the touch is appropriate to the strength of the one-dollar coin on the hand, and the pressure is about 25 to 30 mmHg. Try not to cause skin wrinkles by using light, soft, and shallow touch technique. The affected breast runs along the superficial lymphatic vessels, and the sequence of unarmed lymphatic drainage is divided into four quadrants, the lymph in the upper inner quadrant of the axillary side is caressed and pushed to the supraclavicular lymphatic vessel on the ipsilateral side, and the lymph in the outer upper quadrant of the axillary side is pushed to the ipsilateral supraclavicular lymphatic vessel or cervical lymphatic vessel. The lymph in the internal and external upper quadrant of the contractile breast was pushed to the axillary lymph nodes or supraclavicular lymph nodes, the internal and external lower quadrant lymph [22] [23]. In this group of 5 patients, the affected limbs showed varying degrees of pain and mild edema, which were relieved by unarmed lymphatic drainage by the international lymphoedema therapist.

3.2.3. Skin Observe

Observe the condition of inverted T-shaped skin flap every hour after operation, observe the temperature of T-shaped skin flap and the surrounding skin color,

touch whether there is subcutaneous effusion, as well as finger pressure flap. The normal reaction is 1 to 3 s. If the skin is blue, swelling is severe and the reaction time of finger pressure is more than 5 s, it should be dealt with in time [24]. Observe whether the pressure is too large or insufficient. If so, adjust it in time, and then observe the T-shaped skin flap and nipple areola every 2 hours every day, gently pinch the nipple in each shift, observe the capillary filling degree, and judge the nipple edema. The skin temperature of the affected side is measured by a skin thermometer, and compared with that of the healthy side. If the surrounding skin temperature is higher than that of the opposite side, the contrast temperature is more than 1 degree, or the skin temperature does not rise for a long time, it should be on guard against infection or ischemia [25]. For the T-shaped neck area, evaluate the skin tension around the incision, observe the degree of swelling of the upper breast, and whether there is obvious pressure on the breast. If there is obvious pressure, the upper support can be fixed with an elastic bandage and 2 fingers should be loosened and tightened. Patients are advised to choose a semi-sitting position of 30 - 45 degrees during the day before removing the drainage tube, shake the head of the bed 15 - 30 degrees at night when rest, and do not walk with chest arch when getting out of bed, so as not to aggravate the oppression. After the pressurized bandage is loosened, it is necessary to inform the bed attendant whether to readjust it or not.

4. Discussion

Preoperative new breast location, intraoperative flap repair and postoperative flap nursing are the keys to successful operation. Repeated clipping of blood vessels may cause pedicle injury, but the optimal time interval and cycle of ischemic preconditioning are not clear. Inflammatory reaction can also cause necrosis and ischemia of the flap, aggravate local edema, bleeding, thrombosis and so on. Therefore, reducing the inflammation of the flap can improve the survival rate of the flap.

5. Conclusion

Breast-conserving surgery combined with contralateral breast reduction surgery for breast cancer can not only achieve the therapeutic effect, but also maintain the appearance of the breast, improve the shape of the breast and improve the quality of life of patients. Nursing care of inverted T-shaped flap is the key to smooth recovery after the operation. Pay attention to the blood supply of the neck area of the T-shaped flap, finding abnormalities and deal with them in time, and guarding against ischemic necrosis of skin flap. Unarmed lymphatic drainage can relieve the pain of the affected limb after the operation, promote lymphatic reflux, reduce the edema of the skin flap, and is beneficial to the growth and survival of the flap.

Funding

This study was funded by the 2020 Medical Scientific Research Foundation of

Guangdong Province of China (A2020267).

Ethical Approval

Approval was obtained from the Ethics Committee of Sun Yat-sen University Cancer Center (No. GYX2020-002). The procedures used in this study are in line with the purpose of the Declaration of Helsinki.

Conflicts of Interest

The authors declare no conflicts of interest regarding the publication of this paper.

References

- [1] Li, Y.L., Dai, Y. and Hu, D.Y. (2010) The Studies on Effects of Mastectomy to Sexual Feeling of Breast-Cancer Patients and Their Spouses. *Medicine and Society*, **11**, 81-83.
- [2] Cai, W.R., Yang, Z.J. and Cao, X.C. (2017) Current Situation and Problems of Breast Conserving Surgery. *International Journal of Oncology*, **44**, 550-553.
- [3] Han, J., Quan, H., Liu, J.J., Yan, W.G., Ding, H.Z., Wang, C. and Paliyenka, T. (2019) Inverted-T Pattern Breast Reduction in Breast Hypertrophy Patients with or without Breast Cancer. *Chinese Journal of Breast Disease (Electronic Edition)*, **13**, 75-80.
- [4] Han, J., Quan, H., Liu, J.J., *et al.* (2019) Inverted-T Pattern Breast Reduction in Breast Hypertrophy Patients with or without Breast Cancer. *Chinese Journal of Breast Disease (Electronic Edition)*, **13**, 17-22.
- [5] He, J., Lu, X.-W., Ding, Y. and Mao, J.-F. (2004) Section of Mastotic Tissue and Mastopexy with Double-Ring Periareolar Incisions. *Chinese Journal of Aesthetic Medicine*, **13**, 183-184.
- [6] Duan, X.N. (2018) Review and Revelation of Breast Cancer Surgical Treatment. *China Real Journal of Surgery*, **38**, 1227-1231.
- [7] Bertozzi, N., Pesce, M., Santi, P.L., *et al.* (2017) Tissue Expansion for Breast Reconstruction: Methods and Techniques. *Annals of Medicine and Surgery*, **21**, 34-44. <https://doi.org/10.1016/j.amsu.2017.07.048>
- [8] Bao, C.C., Ma, Y.F. and Tang, G.L. (2021) Research Progress of Adverse Factors and Prevention of Wound Healing after Breast Cancer. *Chinese Journal of Burn Trauma and Selection*, **33**, 259-263.
- [9] Hang, Z.X., Geng, J. and Yi, C.G. (2016) Keep the Clinical Effect of Sutitanic Breast Reduction within Breast Interval. *Chinese Journal of Medical Aesthetics and Beauty*, **22**, 1-3.
- [10] Rao, Y.H., Yang, X.L., Yu, Y., Zhao, S.M., Yan, G.C. and Li, S.L. (2008) Preoperative Design of Inverted T-Shaped Incision. *Chinese Beauty Medicine*, 584-585.
- [11] Ding, W. (2016) Study on the Effect of the Survival of Postoperative Flaps by the Application of Vacuum Sealing Drainage.
- [12] Schlaudraff, K.U., Pepper, M.S., Tkatchouk, E.N., Ehrenburg, I., Alizadeh, N., Montandon, D. and Pittet, B. (2008) Hypoxic Preconditioning Increases Skin Oxygenation and Viability But Does Not Alter VEGF Expression or Vascular Density. *High Altitude Medicine & Biology*, **9**, 76-88. <https://doi.org/10.1089/ham.2008.1006>
- [13] Yang, L. and Bian, W.W. (2019) Observation of Blood Circulation after Flap Trans-

- plantation: A Literature Review. *Chinese Journal of Nursing*, **54**, 1329-1333.
- [14] Pang, Y. (2016) Effect of Vaseline Gauze on Wound Healing of Surgical Incision. *China Medical Device Information*, **22**, 57-58.
- [15] Ding, W. (2016) Study on the Effect of Negative Pressure Suction on the Survival of Flap after Operation. Wannan Medical College, Wuhu.
- [16] Lista, F., Austin, R.E., Singh, Y., et al. (2016) Vertical Scar Reduction Mammoplasty. *Plastic & Reconstructive Surgery*, **136**, 23-25.
<https://doi.org/10.1097/PRS.0000000000001371>
- [17] Feng, J. and Hu, H.Z. (2019) A Novel Player in the Field: Merkel Disc in Touch, Itch and Pain. *Experimental Dermatology*, **28**, 1412-1415.
<https://doi.org/10.1111/exd.13945>
- [18] Xu, D.M., Guo, H.Y., Mi, Z.P. and Zhang, L.L. (2012) Effect of Unarmed Lymph Drainage on TNF- α after Traumatic Swelling in Rats. *Chinese Journal of Clinicians (Electronic Edition)*, **6**, 2520-2521.
- [19] Xu, L. (2012) Effect of Flap Healing after Multi-Point Suture in Breast Cancer Surgery. *Journal of Mathematical Medicine*, **25**, 614-615.
- [20] Zhou, D.X. and Duan, G.S. (2011) Discussion on the Causes and Precautions of Skin Flap Necrosis after Postoperative Breast Cancer. *Chinese General Medicine*, **9**, 1718-1719.
- [21] Xiang, C.Y. (2009) Effect of Safflower Alcohol Wet for Flap Necrosis after Breast Cancer. *Contemporary Nurse (Academic Edition)*, **3**, 74-75.
- [22] Zhang, L.J., Huang, Z.Y., Zhu, X.L., et al. (2015) Effect of Freehand Lymph Drainage to Prevent Upper Limb Lymphedema after Breast Cancer. *Journal of Practical Medicine*, **31**, 2910-2913.
- [23] Zhang, B.-N. (2015) Prevention Strategies and Treatment Principles of Upper Limb Lymphedema after Breast Cancer Operation. *Chinese Journal of Practical Surgery*, **35**, 723-727.
- [24] Ye, L.L. and Chen, L.M. (2011) Perioperative Nursing Care of Large Breast Reduction with Inverted T-Shaped Incision. *Chinese Beauty Medicine*, **20**, 1978-1979.
- [25] Xiong, H.-T., Zhuang, Y.-Q. and Fu, X.-K. (2018) Clinical Observation and Treatment of Abnormal Blood Circulation after Flap Transplantation. *Chinese Journal of Microsurgery*, **41**, 296-298.