



Evaluation of Direct Rapid Immunohistochemistry Test for Rabies Diagnosis in the Brain of Slaughtered Dogs in Northern Nigeria

A. Garba^{1*}, O. V. Modupe², A. A. Dzikwi³, A. A. Ogun⁴, A. Zaharaddeen¹,
F. S. Umar¹, P. A. Okewole¹, J. U. Umoh³, M. S. Ahmed¹, P. Yager²,
L. A. Orciari² and M. Niezgod²

¹Department of Diagnostics and Extension, National Veterinary Research Institute, Vom, Nigeria.

²Rabies Program, Centers for Disease Control and Prevention, Atlanta, GA, USA.

³Department Vet. Public Health and Preventive Medicine, Faculty of Veterinary Medicine, Ahmadu Bello University, Zaria, Nigeria.

⁴Department Research and Innovations, National Universities Commission, Abuja, Nigeria.

Authors' contributions

This work was carried out in collaboration between all authors. Authors AG, JUU and AAD designed the study, ran the laboratory (FAT) work in Zaria, data analysis and drafted the initial manuscript and final review. Authors AG, MSA, PAO, AAO, AZ and FSU designed and involved in sample collection, shipment across the Niger State to Zaria, Nigeria and some literature search. Authors AG, LO, OVM, PY and MN, made necessary arrangements for the shipment of samples to CDC, Atlanta, USA, laboratory procedures (FAT and DRIT), literature review and reviewing of the final draft. All authors read and approved the final manuscript.

Article Information

DOI: 10.9734/AIR/2015/14022

Editor(s):

- (1) Csilla Tothova, University of Veterinary Medicine and Pharmacy in Kosice, Slovakia.
(2) Monica Butnariu, Department of Chemistry & Biochemistry, Banat's University of Agricultural Sciences and Veterinary Medicine from Timisoara, Romania.

Reviewers:

- (1) Omesh Kumar Bharti, Government of Himachal, India.
(2) Anonymous, China.
(3) S. N. Madhusudana, Neurovirology, NIMHANS, Bangalore India.
(4) Anonymous, China.
(5) Anonymous, India.

Complete Peer review History: <http://www.sciencedomain.org/review-history.php?iid=971&id=31&aid=8580>

Original Research Article

Received 15th September 2014
Accepted 8th January 2015
Published 25th March 2015

ABSTRACT

Aim: To compare the ability of the direct rapid immunohistochemistry test (DRIT) and the gold standard test, luorescent antibody test, (FAT) to detect rabies virus antigen in the brains of slaughtered dogs from Niger State in the northern region of Nigeria.

Study Design: Cross sectional.

Place and Duration: Department of Veterinary Public Health, Ahmadu Bello University, Zaria, Nigeria and Rabies Program, Centers for Disease Control and Prevention(CDC), Atlanta, GA, USA, between January, 2012 and February, 2013.

Methodology: Four hundred and seventy one (471) dog brain samples were collected through the occipital foramen from dogs destined for human consumption at five dog slaughter points in Niger State during January and July 2012. Samples were tested by FAT in July, 2012, then the FAT and DRIT were repeated in January, 2013 simultaneously and independently to detect rabies virus antigens.

Results: Of the 471 slaughtered dogs, the same 3 (0.64%) had rabies virus antigens in their brains using both tests. There was absolute agreement between the two tests employed, and all the positive samples had 4+/4+ antigen distribution and the color intensity of the viral antigen.

Conclusion: Detection of rabies viral antigens in slaughtered dogs may pose a serious public health risk, particularly for the dog butchers during purchase, shipment, slaughter and processing periods. The DRIT showed absolute agreement with the standard (FAT), yet does not require an electric incubator and an expensive fluorescence microscope, and thus could be a less expensive alternative test for the detection of rabies virus antigen in slaughtered dogs. It is recommended therefore, to use of DRIT for field surveillance of rabies virus antigen in the brain of slaughtered dogs, particularly in the developing countries where fluorescence microscopy is not readily available due to its prohibitive cost.

Keywords: Evaluation; rabies; DRIT; FAT; dog brain; diagnosis; northern Nigeria.

1. INTRODUCTION

Rabies is a viral zoonotic disease of warm blooded animals and the disease that causes the most agonizing death known to man the world over. Rabies is a major public health problem in most parts of the developing world, where the domestic dog plays a principal role as a reservoir and transmitter of the disease to humans [1]. While bats are the reservoirs of rabies in some parts of the western world, dogs are the major reservoirs of rabies in most developing countries particularly Asia and Africa. Rabies is effectively preventable through vaccination, but early detection and diagnosis of exposure to the virus is essential to make this statement a reality. The laboratory confirmation of rabies virus was first achieved in 1903 with the detection of the presence of Negri bodies in brain tissue of infected animals which is pathognomic for rabies [2] Diagnostic techniques for rabies have been standardized internationally [3]. Histopathological techniques such as the Sellers Stain technique [4] were used to determine the presence of Negri bodies; inclusions, typical of rabies, however, due to poor sensitivity and specificity this technique is no longer recommended by the World Health Organization for diagnosis [5]. The

Mouse Inoculation Test (MIT) [6] and the Rabies Tissue Culture Infection Test (RTCIT) [7] are based on the propagation and isolation of the virus [6]. Unfortunately, both the RTCIT and MIT require a longer period of time (4-days and 28-days, respectively) for a diagnosis to be made, which is a disadvantage to bite victims. The fluorescent antibody test (FAT) relies on the ability of a detector molecule (usually fluorescein isothiocyanate) coupled with rabies specific antibodies (forming a conjugate) to bind to and allow the visualization of rabies virus antigen using fluorescence microscopy techniques [8,9]. The FAT has been recommended as the gold standard technique for rabies diagnosis [3,9]. However, this test requires approximately 2 hours to perform and requires the use of a fluorescence microscope, which is unavailable or cost prohibitive in most laboratories of the developing world countries where the disease is endemic. In numerous laboratories in rabies-endemic regions of the developing world, cost and simplicity are critical factors, even when the principal consideration is for rapid disease diagnosis [8]. To compensate for the use of prohibitive fluorescence microscopy in FAT, a direct rapid immunohistochemistry test (DRIT) for the postmortem detection of rabies virus antigen

in brain impressions has been developed [10]. Using a cocktail of highly concentrated and purified biotinylated monoclonal antibodies, rabies virus antigen can be detected by direct immunostaining of fresh brain impressions within 1 hour. Performed on brain tissues, the DRIT has demonstrated sensitivity which correlates to the FAT for fresh specimens [11, 12, 13]. Field trials in Chad studied the DRIT in direct comparison to the FAT in an attempt to confirm the incidence of rabies from previous studies within an endemic area. In this study, results between the two tests were 100% in agreement [11]. In the present report, DRIT and FAT were run simultaneously and independently on brain samples from dogs slaughtered for human consumption in a state from the Northern region of Nigeria to survey for the presence of rabies virus antigen. This study was carried out to evaluate the appropriateness of adapting the DRIT technique for rabies surveillance, particularly in Nigeria and developing countries where a fluorescence microscope cannot be purchased or maintained for FAT rabies diagnosis in most laboratories.

2. MATERIALS AND METHODS

2.1 Study Area

The study was conducted in Niger State, Nigeria, a state in the northwest to northcentral region of Nigeria. The state is located between Latitudes $8^{\circ} 30' N$ and $11^{\circ} 30' N$ and between Longitudes $3^{\circ} 30' E$ and $7^{\circ} 20' E$, comprising of three senatorial zones (Bida, Kontagora and Minna) with 26 local government areas. The state has a total human population of over 3.9 million [14], with abundant livestock and dog populations (199,812) [15]. The state falls within the Guinea (southern) Savanna Belt of Nigeria, and about 90% of population live in the rural areas farming for subsistence. Niger State is the largest state in the country in terms of land area, which is about 76,000 sq Km (or nearly 9 per cent of Nigeria's total land area). Fig. 1 represents an administrative map of Nigeria in Africa, with Niger State bounded with arrows.

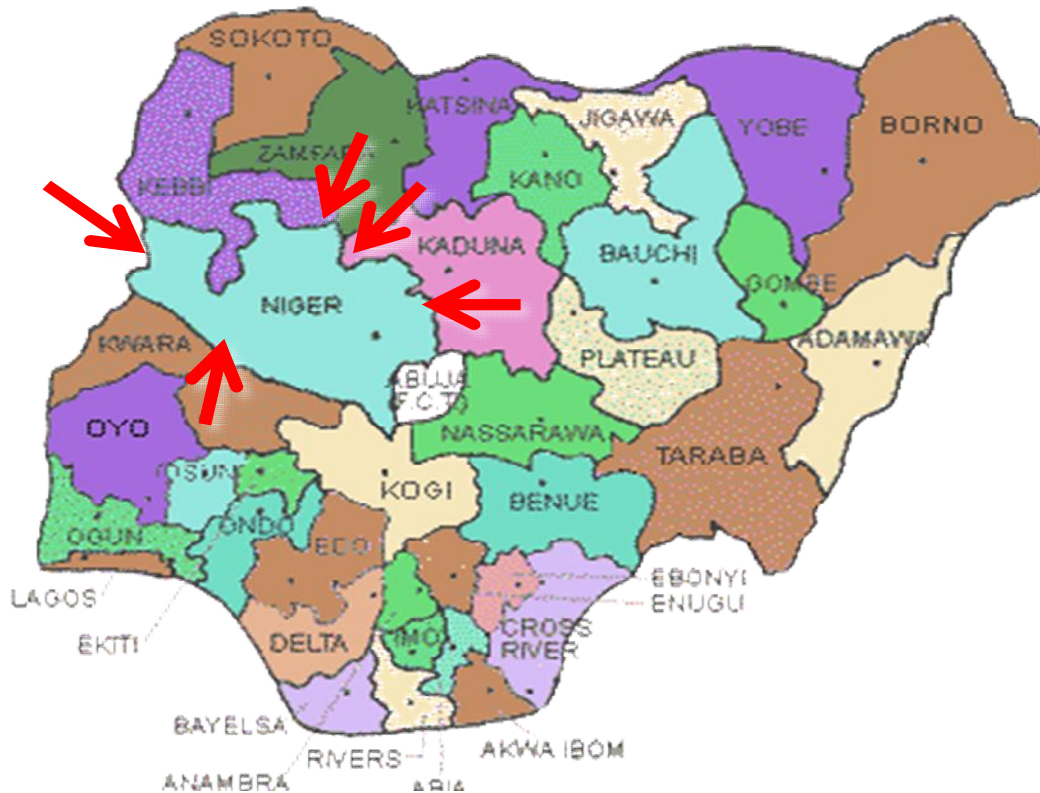


Fig. 1. Administrative map of Nigeria showing 36 states and Abuja (study area Niger State bounded with red arrows)

2.2 Sample Size (n)

Samples size was determined based the previous reported 28% prevalence of laboratory confirmed cases of rabies in apparently healthy slaughtered dogs from northwestern Nigeria [16] using the mathematical expression as described by Mahajan [17]. By the formula ($n = Z^2pq/d^2$) a total of 310 samples was indicated, but this number was exceeded in our study, and 471 dog brain samples were collected and used.

2.3 Sample Collection and Shipment

Five dog slaughter points from four major towns (Bida, Kontagora, Minna and Suleja) were identified and used across the Niger State of Nigeria for sample collection between January and July, 2012. Dogs were examined before slaughter and virtually all were apparently healthy without visible signs of rabies. For every dog slaughtered at the time of the visit, the heads were removed and brain samples were collected via the foramen magnum. The skin and the muscles at the base of the skull were removed, and hacksaw and bone cutters were used to remove a portion of the skull wide enough to obtain brainstem. This sample was transferred to a pre-labelled (plastic) sample bottle. Samples were then shipped on ice to Virology Laboratory, Department of Veterinary Public Health and Preventive Medicine, Ahmadu Bello University (ABU), Zaria, Nigeria. The samples were stored at -20°C until analysed in July, 2012. The samples were later transported on dry ice in September, 2012 to the Rabies Research Program, Centers for Disease Control and Prevention (CDC), Atlanta, GA, USA. All 471 dog brain tissue samples were stored at -80°C for 5 months and re-analysed in January, 2013.

2.4 Laboratory Procedures

Fluorescent antibody testing (FAT) was conducted on all the 471 dog brains at the Virology Laboratory, Department of Veterinary Public Health and Preventive Medicine, Ahmadu Bello University, Zaria Nigeria in July, 2012. Later FAT and DRIT were run in January, 2013 at the CDC to re-evaluate and to confirm the previous results [10,11].

2.4.1 Direct Fluorescent Antibody Test (FAT)

The confirmatory FAT procedure was performed as previously described [9] in accordance with the CDC protocol. Brain impressions were made on 3 well Teflon-coated glass slides, air-dried for

15-30 minutes, then fixed in cold acetone for a minimum of 1 hour. After fixation the impressions were reacted with two anti-rabies nucleocapsid monoclonal antibody conjugates, EMD Millipore Cat# 5100 (Temecula, CA, USA) and Fujirebio Diagnostics, Inc. (Seguin, TX, USA) and specificity negative control conjugate EMD Millipore Cat #5102 during an incubation of 30 minutes at 37°C in a humid chamber. The slides were then removed, and the impressions washed in 0.01M PBS, pH 7.5 twice for 5 minutes each. Coverslips were placed onto the slides using 20% glycerol Tris-buffered mounting medium pH 9.0 and the impressions were observed for the presence of typical rabies-like inclusions demonstrating 4+ sparkling apple green fluorescence under fluorescence microscope at 200x magnification using a 20x aplanachromat objective with > 0.75 aperture. Rabies virus infected and normal mouse brain specimens were used as positive and negative control-slides respectively. Presence of rabies typical apple green fluorescing inclusions in the examination fields of the duplicate impressions tested with anti-rabies conjugates and absence in the impression tested with the specificity control, non-rabies FITC conjugate was considered positive (presence) of rabies viral antigen. The absence of apple green fluorescing particle on the stained impressions was considered negative for rabies. All test slides were compared with the positive and negative controls. Results were recorded according to the intensity and distribution of viral particles graded from +1 (low) to +4 (high) intensity/distribution. Typical rabies virus inclusions demonstrated fluorescence of 4+ intensity.

2.4.2 Direct rapid immunohistochemistry test (DRIT) procedure

All the brain samples from dogs were also subjected to DRIT procedure as described [10, 13] at the CDC. Duplicates of the brain impressions for DRIT were made at the same time as for the FAT and included all the 471 dog samples, and the test positive and the negative control impressions. These impressions were air-dried for 5 minutes and fixed in formalin for 10 minutes, removed and dip-rinsed (10 – 15 times) into 1% Tween Phosphate Buffered Saline (TPBS) solution, then placed in hydrogen peroxide (H₂O₂) for 10 minutes, dip-rinsed again in 2 separate containers of TPBS, then overlaid with biotinylated rabies monoclonal antibody for 10 minutes at room temperature in humid chamber. This was followed by a dip-rinsing in

TPBS and impressions overlaid with streptavidin-peroxidase for 10 minutes at room temperature in humid chamber. Then slides were dip-rinsed in TPBS and overlaid with 6-Amino-9-Ethyl-cabarzol (AEC) working solution for 10 minutes at room temperature in humid chamber. Finally, the slides were dip-rinsed in de-ionized water and immersed in 2% Gill's hematoxylin (counterstain) for 2 minutes, then dip-rinsed in de-ionized water 10 -15 times in three separate containers to remove excess stain. Cover slips were placed over the impressions using the aqueous mounting medium ImmunoHistomount™ Sigma (ST Louis, MO, USA). Impressions were then viewed with a light microscope at 200x to 400x magnification using a 20x objective to scan the fields and 40x objective for increase magnification and greater resolution. The presence of bright red typical rabies inclusions on bluish counterstained background indicated (positive) presence of rabies antigens, while bluish background only, indicated the sample was negative (absence of rabies antigen). Distribution and intensity were recorded from +1 (low) to +4 (high). Positive samples demonstrated by 4+ intensity bright red inclusions. Low intensity coloration (light red or pink) is indicative of a non-specific reaction.

2.5 Kappa Statistical Testing for Agreement

The results of DRIT and FAT were entered into a 4x4 contingency table and were subjected to Kappa statistical test for agreement between the two tests as described [18]. *Kappa coefficient (value)* of 0 – 0.2 = no agreement, 0.2 – 0.4 = moderate agreement, 0.6 – 0.8 = good agreement, 0.9 – 1 = absolute agreement [18]

3. RESULTS

The results demonstrated that of the 471 dog brain sample analysed by FAT and DRIT, 3 (0.64%) samples were positive for rabies antigen

with 100% agreement between the 2 tests employed (Table 1). Furthermore, the positive samples agreed 100% in the distribution and intensity of the viral antigen (4+/4+) with both techniques (Table 1, Figs. 2 and 3).

The samples that were positive when analysed by FAT in July, 2012, in ABU, Nigeria still remained positive when re-analysed with FAT and DRIT in January, 2013 at CDC, Atlanta, USA (Table 2).

4. DISCUSSION

It has been observed that of the 471 dog brain sample analysed by FAT and DRIT, 3 (0.64%) samples were positive for rabies virus antigen with 100% agreement between the two tests (FAT and DRIT) employed. This outcome has again confirmed the presence of dog rabies in the dog population rendered as food source in Niger State of Nigeria. This further emphasizes the relevance of rabies surveillance in butchered dogs. It is of public health significance that the (0.64%) occurrence of rabies (in butchered dogs) would have been missed if only the samples submitted to the Rabies Diagnostic Laboratory, National Veterinary Research Institute (NVRI), Vom, Nigeria were included in the calculations of incidence of rabies cases in Nigeria. Previously, the incidence of rabies in suspected animal samples submitted to NVRI between 1991 and 2005 was reported to be 45.5% [19]. Despite the presence of rabies in the butchered dogs in the present study area, the percentage (0.64%) is very low compared to high percentages (between 6 and 42.2%) in butchered dogs reported by other researchers from various states in Northern Nigeria [16, 19, 20, 21, 22, 23]. This low percentage in the present report may imply that there was low circulation of the rabies virus amongst the dog population in Niger State of Nigeria (the study area) from January to July, 2012.

Table 1. Brain Samples from apparently healthy slaughtered dogs diagnose positive for rabies antigen

Diagnostic method	Total no. of samples	No. positive	%age positive	Samples positive	Intensity/distribution
FAT	471	3	0.64%	D252, D276, D471	4+/4+ “ “
DRIT	471	3	0.64%	D252, D276, D471	4+/4+ “ “

Kappa coefficient between tests = 1 (absolute agreement)

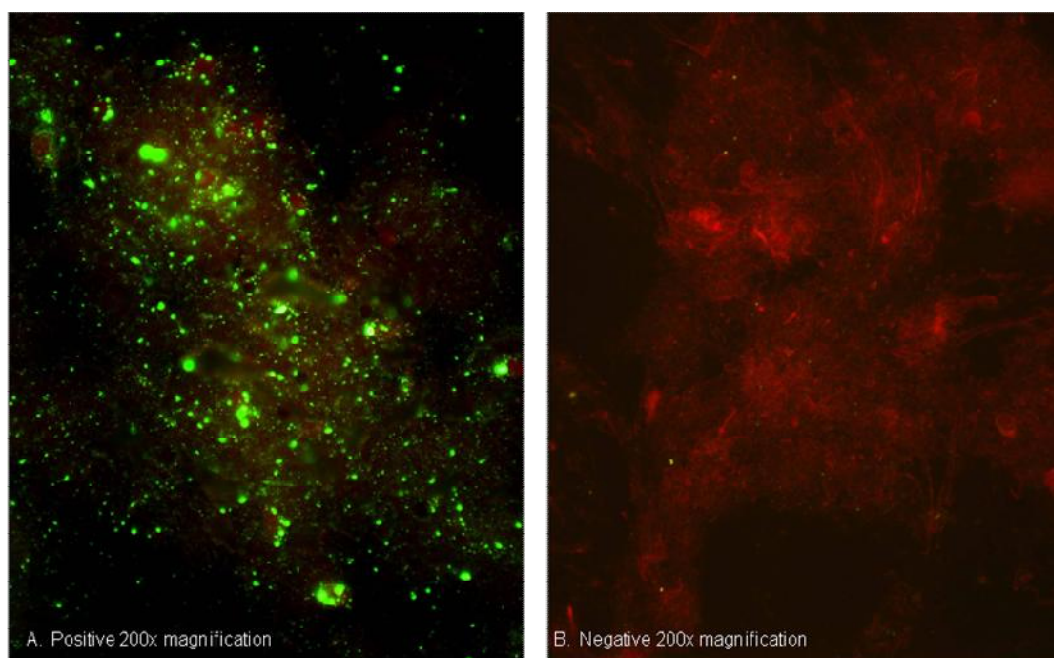


Fig. 2. The direct fluorescent antibody (DFA) test slide on fresh brain touch impression showing +4/+4 high distribution and intensity of the viral N protein by apple green fluorescing particles A= Positive. And none in B= Negative. Picture taken at CDC

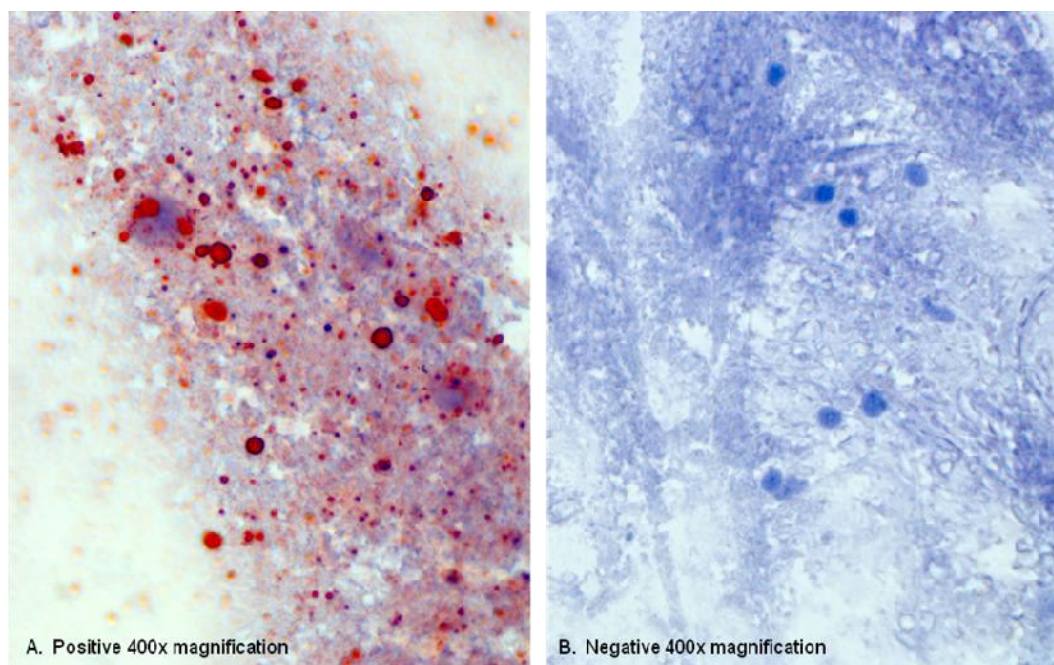


Fig. 3. Examples of the positive and negative DRIT slides, photos provided by CDC and previously presented [13]. The direct rapid immunohistochemistry test (DRIT) slide on fresh brain touch impressions showing +4/+4 high distribution and intensity of the viral N protein by deep red particles A= Positive. And none in B= Negative

Table 2. Samples collection identity, period of collection and laboratory of analyses January, 2012 – January, 2013

Range of samples ID	No. of samples collected	Month Sample Collected	Date 1 st testing conducted ABU (FAT)	Date 2 nd tests conducted, CDC (FAT & DRIT)	No. positive (%)
D001 –D032	32	Jan, 2012	July, 2012	Jan, 2013	0
D033 – D040	8	Feb, 2012	“	“	0
D041 – D048	8	Mar,2012	“	“	0
D049 – D075	26	Apr, 2012	“	“	0
D076 – D179	103	May,2012	“	“	0
D180 – D402	222	Jun, 2012	“	“	2
D403 – D471	69	Jul, 2012	“	“	1
Total	471	7 months	July, 2012	Jan., 2013	3 (0.64)

Key: ABU = Ahmadu Bello University, Zaria- Nigeria, CDC = Centers for Disease Control and Prevention, Atlanta, USA, ID = Identity, D = dog

The 100% concordance between FAT and DRIT suggests that in this sample set of butchered dogs, the DRIT technique has demonstrated sensitivity and specificity equal to the gold standard FAT technique on brain samples from butchered ed dogs as previously reported [11,12,13,24]. The long storage and quality of the samples does not seem to have affected the results of analyses when comparing the July, 2012 FAT and those obtained in January, 2013 using FAT and DRIT. It was observed that the highest positivity rate (2 out of 3 positives) was among samples collected in June, towards the end of the samples collection period. This may be as a result of dog butchers' awareness and acceptance of the research by mid-study and towards the end of the sample collection period. Hence more samples collected and more positives in June.

In this study, the 3 positive samples with observed high distribution and intensity of the antigen (4+/4+) demonstrated the presence of rabies virus infection in the brains of apparently healthy butchered dogs destined for human consumption. The public health implication of this finding is that the dog butchers, dog consumers and dog owners could be infected with rabies virus through contact with the infectious materials during and after the processing period. Furthermore, the housing, handling, purchase and shipment of apparently healthy dogs, but with rabies virus infection in their brains (and potential presence in saliva) may aid in the disease transmission and maintenance of rabies virus in the dog and human populations within the study area. It should be noted, however, that oral infection with the rabies virus (through the eating of tissues from a rabid dog) may not cause rabies infection

if the cooking or roasting temperature is sufficient to kill the virus. In addition, low pH of HCl acid in the stomach may inactivate rabies virus. However, if insufficiently cooked tissues are ingested, there is the potential for pre-gastric infection of oral cavity tissues (i.e. buccal mucosa, tonsils, tongue, etc.). Furthermore, the observation of 4+ distribution and 4+ intensity of rabies virus antigen in the brains of the positive dogs may suggest that the dogs were expressing non-aggressive signs consistent with paralytic “dumb” form of rabies, and the early signs (lethargic, cowering state) not recognized for rabies or misinterpreted as environmental apprehension at the point of slaughter.

The question is how healthy are the so called apparently healthy dogs? In the present study, the dogs were visually examined in their cages before slaughter and were apparently healthy dogs and hence assumed to be rabies free. However, the presence of rabies antibodies has been documented in 15.93% of unvaccinated dogs examined from southern Nigeria [25]. This suggests that such dogs were previously infected with the virus, but remaining apparently healthy expressing the presence of such antibodies in that report [25]. Furthermore, Fekadu (1988) reported that up to 20% of dogs experimentally infected with a street rabies virus that were initially showing signs recovered without any supportive treatment, and he concluded that rabies is not invariably fatal [26]. In another report, two of the dogs, inoculated with a rabies virus strain from Ethiopia recovered from clinical rabies [27]. In other words, rabies carrier state or inapparent infection and the presence of rabies antigens and antibodies in apparently healthy dogs have been a subject of research in Nigeria and elsewhere in the world [16,20,21,

22,23,28,29,30,31]. Additional research, however, is necessary to answer these questions.

In addition, this study has demonstrated the practical application and cost effectiveness of the DRIT as an alternate test for post-mortem diagnosis of rabies in animals. There was 100% agreement when DRIT results were compared to the results of the same samples tested by the FAT. The cost of a fluorescence microscope (used in the FAT) was quoted as ten times higher than the cost of a light microscope (used in the DRIT) [11]. The utilization of a simple light microscope for observation of rabies virus antigen in the DRIT technique is a major advantage since light microscopes are readily available and affordable even in low income countries where rabies may be under diagnosed and under reported [32].

4. CONCLUSION

Based on the outcome of this research, the DRIT appears to be an excellent diagnostic tool for field surveillance of rabies antigen in Nigeria and other developing countries. The test is particularly suited to low income countries where a constant supply of electricity is rare. Therefore, the use of DRIT technique for rabies virus diagnosis in butchered dogs across the states of Nigeria will greatly enhance the diagnostic capability and rabies surveillance in Nigeria. Although the test components such as streptavidin-peroxidase reagent and the AEC stock component buffers and working solutions, slides and mounting media are all commercially available, a major limitation is the lack of a commercial source for the biotinylated rabies monoclonal antibodies to meet the growing global needs.

The recent WHO Expert Consultation on Rabies, Second Report, 2013 [33], recognized the DRIT as a test which has produced consistently reproducible results in some laboratories, and that evaluation has shown sensitivity and specificity are comparable to those of the FAT [33]. It further recognized the advantage of this technique in enhancing rabies surveillance since the procedure requires only a light microscope. In addition, the Consultation recommended further development of DRIT based tests as an alternative to the FAT, and potential usefulness of the test if the additional reagents become available commercially.

ACKNOWLEDGEMENTS

We greatly appreciate the support of the management of the National Veterinary Research Institute, Vom- Nigeria, Department of Veterinary Public Health, Faculty of Veterinary Medicine, ABU, Zaria-Nigeria and the Rabies Program, CDC, Atlanta, USA for providing the reagents, materials and laboratory facilities for this research. The academic support given by Prof. H.M Kazeem (Head of Microbiology department and Dean of the faculty of veterinary Medicine, ABU, Zaria Nigeria) is hereby acknowledged. Support from dog butchers (too numerous to mention) across the Niger State is also acknowledged. Niger State Government, NVRI, Vom, Col. Sani Bello RTD and Sen. (Barr).Ibrahim Musa offered some financial assistance in shipment of samples and logistics to the USA, and are hereby acknowledged

Dr. Garba is a doctoral candidate in the department of Veterinary Public Health and Preventive Medicine, Ahmadu Bello University, Zaria, Nigeria and an employee of the National Veterinary Research Institute, Vom-Nigeria.

ETHICAL APPROVAL

Ethical approval has been given both from the state ethics committee and the Ahmadu Bello University, Ethics committee (ABUTH/HREC/TRG/36). Similarly, we hereby declare that "Principles of laboratory animal care" (NIH publication No. 85-23, revised 1985) were followed, as well as specific national laws. All experiments have been examined and approved by the appropriate ethics committee".

DISCLAIMER

The findings and conclusions in this report are those of the author(s) and do not necessarily represent the views of the funding agency.

COMPETING INTERESTS

Authors have declared that no competing interests exist.

REFERENCES

1. World Health Organization. WHO Expert Committee report on Rabies. WHO Technical Report Series No.824, Geneva; 1992.

2. Negri A. Zentrabiol. Hygiene Infektionski. Italiana, 1903;43:507.
3. Office International des Epizooties. OIE manual on rabies. 2000;277-291.
4. Tierkel ES, Atanasiu P. Rapid microscopic examination for Negri bodies and preparation of specimens for biological tests. In: Meslin F-X, Kaplan MM, Kowprowski H, editors. Laboratory Techniques in Rabies. 4th Edition. Geneva. World Health Organization. 1996;55–65.
5. World Health Organization. WHO Expert Committee Report on Rabies. Technical Report Series No.523, 6th Report; 1973.
6. Webster LT, Dawson JR. Early diagnosis of rabies by mouse inoculation. Measurement of humoral immunity to rabies by mouse protection test. Proc Soc Exp Biol, Med. 1935;32:570–573.
7. Sureau P. Les techniques rapides de diagnostic de laboratoire de la rage. Arch Inst Pasteur Tunis. 1986;63:183–197.
8. Fooks AR, Johnson N, Freulling CM, Wakeley PR, Banyard AC, McElhinney, et al. Emerging technologies for detection of rabies virus: Challenges and hopes in the 21st century. PLoS Neglected Tropical Diseases. 2009;3(9):e530. DOI:10.1371/journal.pntd.0000530.
9. CDC. Protocol for postmortem diagnosis of rabies in animals by direct fluorescent antibody testing: a minimum standard for rabies diagnosis in the United States. Atlanta: CDC; 2003. Accessed Nov 15, 2014. Available:www.cdc.gov/rabies/pdf/rabiesdfaspv2.pdf
10. CDC. Centers for Disease Control and Prevention Standard Operating Procedure for Direct rapid immunohistochemistry test (DRIT) for the detection of rabies virus antigen; 2006.
11. Durr S, Nai'ssengar S, Mindekem R, Diguimbye C, Niezgoda M, Kuzmin I, et al. Rabies diagnosis for Developing Countries. PLOS Neglected Tropical Diseases. 2008;2(3):1–6.
12. Tao XY, Niezgoda M, Du JL, Li H, Wang XG, Huang Y, et al. The primary application of direct rapid Immunohistochemical test to rabies diagnosis in China. Zhonghua Shi Yan He Lin Chuang Bing Du Xue Za Zhi. 2008;22:168–170.
13. Lembo T, Niezgoda M, Velasco-Villa A, Cleaveland S, Ernest E, Rupprecht CE Evaluation of a direct, rapid Immunohistochemical test for rabies diagnosis. Emerging Infectious Diseases. 2006; 12:310–313.
14. NPC. National Population Commission National Census. State Population; 2006. Accessed, 13th May, 2014. Available:<http://www.population.gov.ng/index.php/state-population>
15. RIM. Federal Department of Livestock and Pest Control Services. Nigeria Livestock Resources. National Synthesis. Resources Inventory and Management Ltd; St. Helier, Jersey, U.K. 1992;2.
16. Garba A, Oboegbulem SI, Junaidu AU, Magaji AA, Umoh JU, Ahmed A, et al. Rabies virus antigen in the brains of apparently healthy slaughtered dogs in Sokoto and Katsina States, Nigeria. Nigerian Journal of Parasitology. 2010;31(2):123-125.
17. Mahajan BK. Methods in biostatistics for medical students and research workers. 6th ed. Jaypee Brothers Medical Publishers Ltd., India. 1997;88-94.
18. Noordhuizen JPTM, Frankena K, Vander Hoofd CM, Graat EAM. In: application of quantitative method in veterinary epidemiology. Wagen Pers, Netherland. 1997;81-82.
19. Garba A, Oboegbulem SI, Lombin LH, Makinde AA, Ogunsan AE, Meseko CA, et al. A 15 year (1991-2005) retrospective study on rabies in Vom, Nigeria. Vom Journal of Veterinary Science. 2008;5(1):54-58.
20. Ajayi BB, Rabo JS, Baba SS. Rabies in apparently healthy dogs histological and Immunohistochemical studies. The Nigerian Postgraduate Medical Journal, 2006;13(2):128-134.
21. Dzikwi AA. The role of dogs and bats in the epidemiology of lyssavirus infection in northern Nigeria. PhD Dissertation, Ahmadu Bello University, Zaria – Nigeria; 2008.
22. Sabo, G. The role of dog trade in the epidemiology of rabies in Plateau State, Nigeria. MSc thesis submitted to the Department of Veterinary Public Health and Preventive Medicine, Ahmadu Bello University, Zaria; 2009.
23. Audu SW. Prevalence of rabies virus in apparently healthy dogs slaughtered for human consumption in Kaduna. M.Sc Thesis, Faculty of Veterinary Medicine, Ahmadu Bello University, Zaria, Kaduna, Nigeria; 2011.

24. Madhusudana SN, Subha S, Thankappan U, Ashwin YB. Evaluation of a Direct Rapid Immunohistochemical Test (dRIT) for Rapid Diagnosis of Rabies in Animals and Humans. VIROLOGICA SINICA. 2012; 27(5):299-302.
DOI: 10.1007/s12250-012-3265-6.
25. Aghomo OH, Oduye OO, Tomori O. Ibe M. A serological survey of rabies virus antibodies in unvaccinated dogs from four states of Nigeria. Zariya Veterinarian. 1987;2(2):71-73.
26. Fekadu M. Pathogenesis of rabies virus infection in dogs. Review of Infectious Diseases. 1988;10(4):678-83.
27. Fekadu M, Baer GM. Recovery from rabies of two dogs inoculated with rabies virus strain from Ethiopia. American Journal of Veterinary Research. 1980;40(10):1632-1634.
28. Bell JF. Latency and abortive rabies. In: The Natural History of Rabies G.M Baer (ed.). 1975;1:331-350.
29. Gribencha SV. Abortive rabies in rabbits and white rats infected intracerebrally. Arch. Virology. 1975;49(4):317-322.
30. Fekadu M, Shaddock JH, Chandler FW, Baer GM. Rabies virus in the tonsils of a carrier dog. Archives of Virology. 1983;78(1-2):37-47.
31. Aghomo OH, Rupprecht CE. Further studies on rabies virus isolated from healthy dogs in Nigeria. Veterinary Microbiology. 1990;22:17-22.
32. World Health Organization. WHO Position paper; Rabies Facts sheets: Immunization, vaccines and Biologicals; 2010. Accessed on 25/9/2010.
Available:<http://www.who.int/immunization/topics/rabies/en/index.html>
33. World Health Organization. WHO Expert Consultation on Rabies, Second Report; 2013. Accessed on 03/11/2014.
Available:<http://www.barnesandnoble.com/w/who-expert-consultation-on-rabies-world-health-organization/1117607782?ean=9789241209823>

© 2015 Garba et al.; This is an Open Access article distributed under the terms of the Creative Commons Attribution License (<http://creativecommons.org/licenses/by/4.0>), which permits unrestricted use, distribution, and reproduction in any medium, provided the original work is properly cited.

Peer-review history:

The peer review history for this paper can be accessed here:
<http://www.sciencedomain.org/review-history.php?iid=971&id=31&aid=8580>