



Non-surgical Management of Large Periapical Lesions with the Agreement Evaluation of the Methods

B. G. M. Lakmali¹, Lakshika S. Nawarathna^{1*} and M. C. N. Fonseka²

¹Department of Statistics and Computer Science, University of Peradeniya, Peradeniya, 20400, Sri Lanka.

²Department of Restorative Dentistry, Faculty of Dental Sciences, University of Peradeniya, Peradeniya, 20400, Sri Lanka.

Authors' contributions

This work was carried out in collaboration among all authors. All authors read and approved the final manuscript.

Article Information

DOI: 10.9734/AJPAS/2019/v5i1130125

Editor(s):

(1) Manuel Alberto M. Ferreira, Lisbon University, Portugal.

Reviewers:

(1) Kumuda Rao, NITTE University, India.

(2) Niladri Maiti, Kims Dental College, India.

(3) Janti Sudiono, Trisakti University, Indonesia.

Complete Peer review History: <http://www.sdiarticle3.com/review-history/50952>

Received: 12 June 2019

Accepted: 23 August 2019

Published: 30 August 2019

Original Research Article

Abstract

Aim: The aim of this study is to evaluate the agreement between three routinely used non-surgical management techniques for large periapical lesions namely the treatments with Calcium hydroxide, Mineralo-Trioxide Aggregate and Bio-dentine.

Methods: Data was collected from 60 patients at the Department of Restorative Dentistry, Faculty of Dental Sciences, University of Peradeniya. The variables age, gender and area of the infected region before and after the treatment and the treatment type were considered. Two homoscedastic and heteroscedastic Mixed-effects models were fitted and the agreement between three treatments were assessed using Concordance Correlation Coefficient (CCC) and Total Deviation Index (TDI).

Results: CCC value calculated for treatment types 1 & 2, 1 & 3 and 2 & 3 are (0.905, 0.909, 0.874) for homoscedastic model and (0.989, 0.990, 0.975) for heteroscedastic model. Further, corresponding TDI values for homoscedastic and heteroscedastic models are (3.148, 4.390, 1.647) and (2.963, 4.388, 1.457) respectively.

Conclusions: Since all the CCC values are close to 1 and TDI values are low, there is a strong agreement between all three treatments and hence they be used interchangeably. Moreover, the agreement between

*Corresponding author: E-mail: lakshikas@pdn.ac.lk;

Treatments with Calcium hydroxide and Bio-dentine is higher compared to the agreements between the other treatments. (i.e., Calcium hydroxide with Mineralo-Trioxide Aggregate and Biodentine with Mineralo-Trioxide Aggregate).

Keywords: Agreement; concordance correlation coefficient; mixed effects models; periapical lesions; total deviation index.

1 Introduction

Inflammatory lesions of the pulp and periapical area which are commonly known as periapical lesions are the most common pathologic condition involving teeth. The lesions are caused by a bacterial infection of the dental pulp [1]. Most of the periapical lesions (>90%) can be classified as dental abscesses granulomas or radicular cysts [2,3]. The occurrence of dental granulomas ranges between (9.3-87.1) % while the incidence of cysts lies within 6-55% and of abscesses between 28.7 and 70.07% [4,5]. A granuloma is formed when the periapical tissues neutralize and confine the irritating toxic products escaping from the root canal. A radicular cyst has its origin from the cell rests of Malassez which are present in periodontal and periapical ligament, and in periapical granulomas. Most radicular cysts originate from pre-existing granulomas. On the other hand, an apical abscess usually develops from a pulpo-periapical inflammatory condition. It also can arise from a pre-existing granuloma or cyst. Cysts and granulomas may present very similarly and on most occasions are hard to distinguish by simple observation. Only a professional can differentiate them. Periapical lesions are diagnosed either during routine dental radiographic examination or following acute pain in a tooth [6]. It is accepted that all inflammatory periapical lesions should be initially treated with conservative nonsurgical procedures [7]. Surgical procedures are recommended only in situations where nonsurgical techniques have failed [8]. In most situations endodontic therapy alone is enough to return the infected teeth to a healthy state and function without surgical intervention since surgery has many drawbacks [9,10], which limit its use in management of periapical lesions. Studies [11] have reported that a high percentage of 94.4% of complete and partial healing of periapical lesions could be achieved by nonsurgical endodontic therapy.

A nonsurgical approach should always be adopted before resorting to surgery. Patients are also psychologically more anxious about surgical treatment than a nonsurgical one. There are several nonsurgical procedures [12,13], such as Conservative root canal treatment without adjunctive therapy, Decompression technique, Intra-canal dressing with Calcium hydroxide, Placement of Mineralo-Trioxide Aggregate (MTA) in the apical 4-5mm of the tooth and Placement of Bio-dentine in the apical 4-5mm of the tooth.

Calcium hydroxide is a material widely used in endodontic treatment because of its bactericidal effects. It is thought to create favorable conditions for periapical repair and stimulate hard tissue formation. A high degree of success has been reported by using calcium hydroxide beyond the apex in cases with large periapical lesions [14]. The treatment should be given repeatedly. However this treatment is economical compared to the others.

Studies [15] have reported that, about one male patient (out of 10 male patients), having a 3mm large lesion showed up a complete healing after 40 days of treatment [15]. However, 35% of the patients healed after 60 days of treatment (40% of female patients and 30% of in male patients). Further, they have stated that, about 30% of lesions of females healed at 90 days post treatment compared to none in males. However, in general the longest healing time in both genders was 120 days post treatment [15]. The healing of periapical lesions in their study was examined by radiographs (Fig. 1).

In the Fig. 1, the upper panel shows the effect of calcium hydroxide leading to a graduate healing of lesions in male patients, whereas the lower panel denotes the healing of lesions in female patients.

Here, the diagrams (a) and (f) show the identification of lesion under radiolucency criteria. The diagrams (b) and (g) show the lesions filling with calcium hydroxide-iodoform-silicon oil paste either in full as in a male

patient or partially as in a female patient. The follow-ups after 10 days are shown by diagrams (c) and (d) where they exhibit a clear degradation of the paste and lesser radiolucency in the lesion. Similarly, the diagrams (d) and (i) shows the 60-day post treatment, where the bone quality has been improved proportionally to material retention. Finally (e) and (j) give the full resorption of the paste with complete bone healing [15].

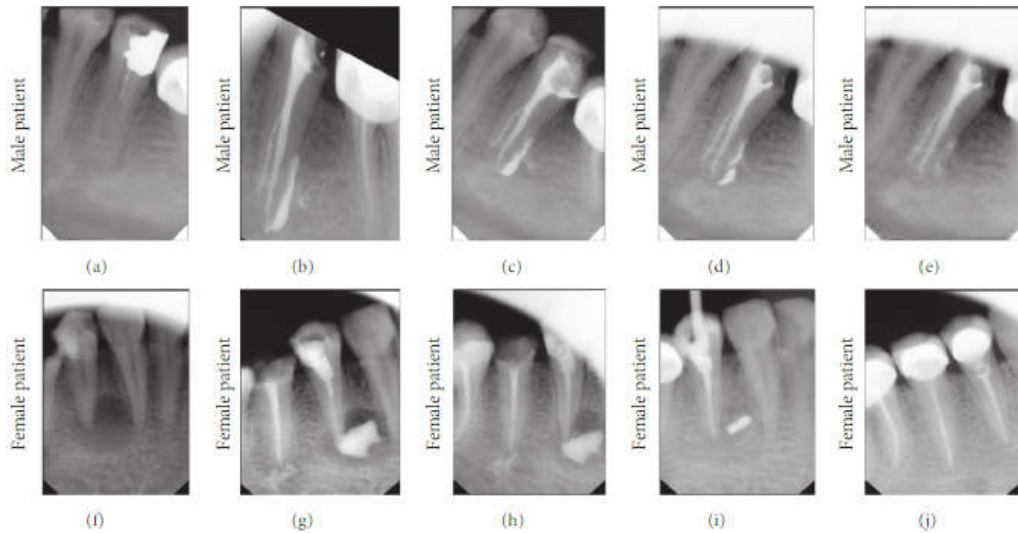


Fig. 1. Randomly selected cases to represent the healing pattern of periapical lesions when using calcium hydroxide-iodoform-silicon oil paste

MTA and Biodentine are more novel materials which are recommended to be used for successful apical closure in cases with large periapical lesions. They are considered extremely bio-compatible and have cemento-conductive and osseo-conductive properties. Thus these materials are increasingly used in the management of large periapical lesions. They are considered more advantageous considering the time taken for apical closure and the superior apical seal they offer [16]. However, compared with calcium hydroxide the cost of these two treatment modalities are higher. The main advantage of these treatment modalities is that the treatment could be dispensed in one visit.

A research [17] was carried out by Kunhappan (2016) to study about the use of MTA and triple antibiotic paste in healing of large periapical lesions. The follow-up radiographs shows the apical seal of MTA and the effect of the apical seal on the lesions after 6 months and 1 year.

Here in the Fig. 2, the following are represented by each diagram.

- a. Infected area before the treatment with MTA
- b. MTA apical plug
- c. Gutta-percha obturation
- d. Follow-up radiograph of 6 months
- e. Follow-up radiograph of 1 year

It has been proved that, even large periapical lesions can respond favorably to nonsurgical treatment with MTA and triple antibiotic paste [17].

Sarang et al. [18] has used Biodentine and Platelet-rich Fibrin in healing large periapical lesions nonsurgically in their study. The follow-up radiographs are given in the figure.

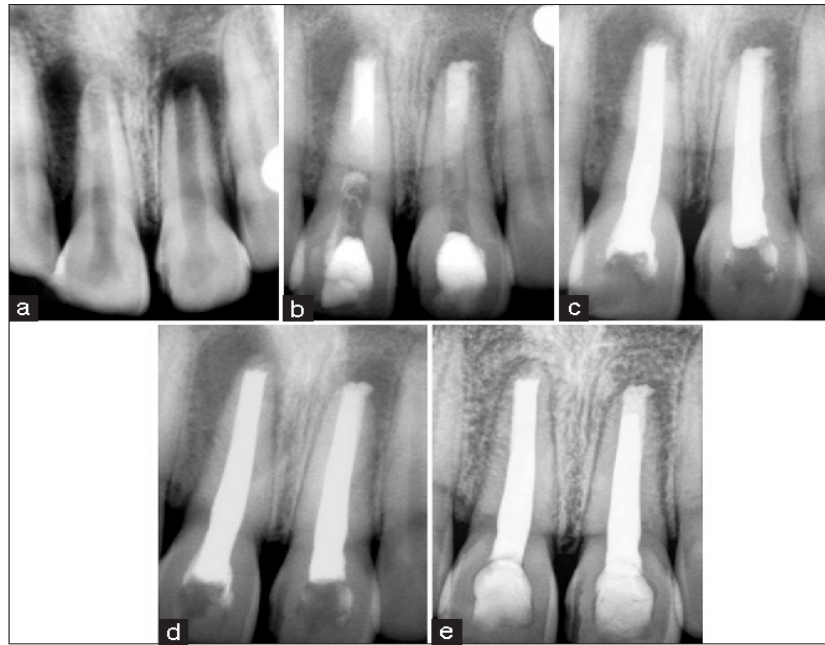

Fig. 2. Radiograph images showing the radiolucent area before and after the treatment with MTA

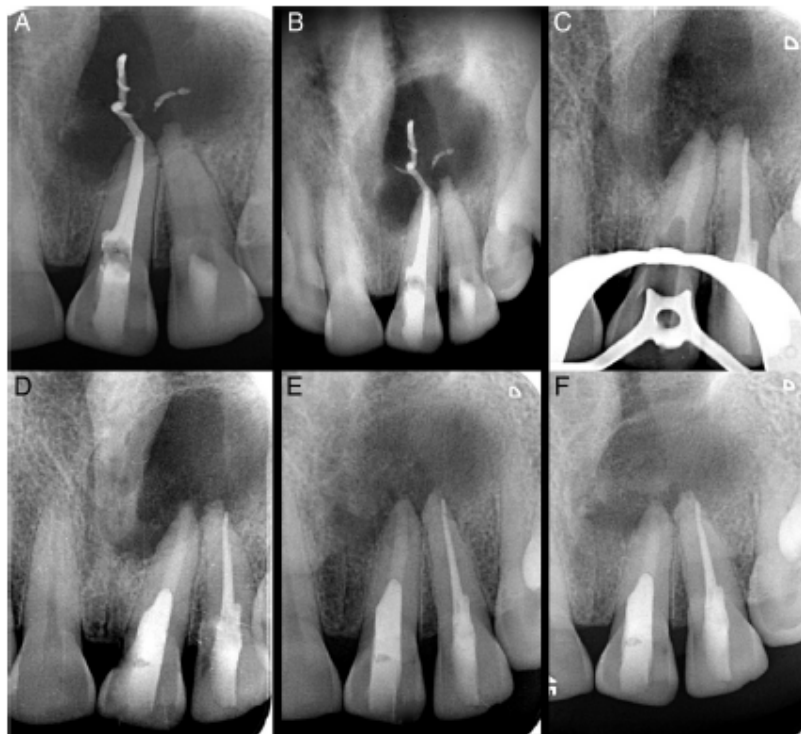

Fig. 3. Radiograph images showing the radiolucent area before and after the treatment with Biodentine and PRF

Here in the Fig. 3, the following are represented by each diagram.

- A. Periapical radiographs showing a large radiolucency involving teeth
- B. Periapical radiographs showing a large radiolucency involving teeth
- C. An intraoperative radiograph showing the apical barrier
- D. Apical Plug of Biodentine and PRF
- E. Follow-up radiograph of 3 months
- F. Follow-up radiograph of 6 months

The study has concluded a collective approach strategy involving 1-step apexification using PRF and Biodentine and supplemented with lesion decompression under a stringent disinfection protocol proved highly successful in enabling teeth with open apices and large periapical/cystic lesions to return to a state of health and function without surgical intervention [18].

The main objective of the present study is to evaluate the agreement between three routinely used non-surgical management techniques for large periapical lesions namely the treatment with Calcium hydroxide (Treatment 1) which serves as the standard reference method, the treatment with Mineralo-Trioxide Aggregate (Treatment 2) and the treatment with Bio-dentine (Treatment 3). If the treatments agree satisfactorily well, then they can be used interchangeably.

2 Materials and Methods

The data was collected from the Department of Restorative Dentistry, Faculty of Dental Sciences, University of Peradeniya. Sixty patients exhibiting well circumscribed periapical lesions of more than 5mm in diameter on a pre-operative periapical radiograph, were randomly allocated to three groups according to the treatment given. The variables considered in this study are the age and gender of the patient, area of the infected region before and after the treatment and the treatment type. The infected area of the tooth of each patient was recorded under 5-time periods (0, 1, 3, 6, 12 months periods) as realized on periapical radiographs taken using a long cone paralleling technique. The maximum diameter of the lesions was recorded at each review as understood on an illuminated radiograph viewer under x2.5 magnification.

In this study, the Wilcoxon Rank Sum Test was used to test the significant difference between the Treatment types. The null hypothesis is that there is no significant difference between the two treatment methods while the alternative hypothesis is that there is a significant difference between the two treatment methods. If $p\text{-value} < 0.05$, we reject H_0 and conclude that there is a significant difference between the two treatment methods.

At first, the data was modeled using homoscedastic mixed-effects model. Then for the situations where the key assumptions such as constant error variance (homoscedastic error variance) are violated, a multiple heteroscedastic mixed effects model was used to model the data. The fitted model was validated using the 10-fold cross validation technique [19,20]. In order to assess the agreement between the three treatments, Concordance Correlation Coefficient (CCC) and Total Deviation Index (TDI) were used [21]. Fisher's z-transformation and the log-transformation were used on the CCC and TDI respectively for greater accuracy.

The CCC is defined as,

$$P_{ccc} = \frac{2\sigma_{12}}{\sigma_1^2 + \sigma_2^2 + (\mu_1 - \mu_2)^2}$$

Here σ_1 and σ_2 are the standard deviations of the two groups being compared while σ_{12} is the covariance between the two groups. μ_1 and μ_2 are the means of group 1 and group 2 respectively.

Total deviation index for the two variables Y_1 and Y_2 is given by,

$$TDI = \sqrt{\chi^{2(-1)}\left(\pi_0, 1, \frac{\mu_d^2}{\sigma_d^2}\right)}$$

Here, TDI is the π_0^{th} percentile of $|Y_1 - Y_2|$, for a given large probability π_0 where $0.80 \leq \pi_0 \leq 0.95$.

3 Results

Most patients with periapical lesions belonged to the below 30 year age group (Fig. 4).

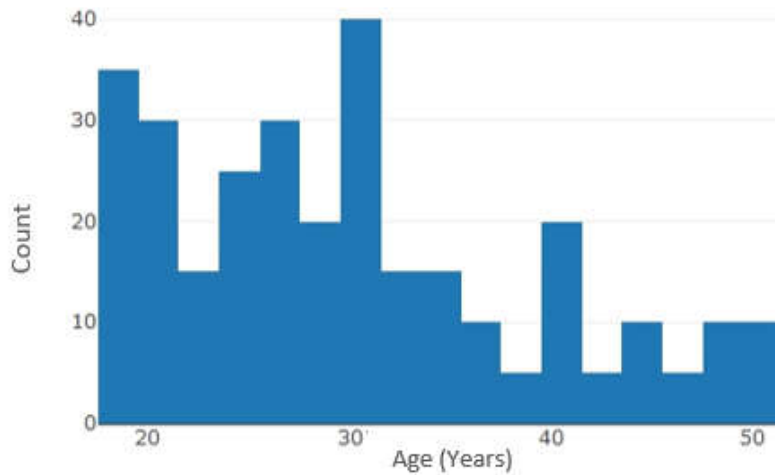


Fig. 4. The Plot of count based on the age of the participants

Fig. 5 implies that Treatment 1 was mostly given to the patients above 30 years, while the other two treatments (Treatment 2 and Treatment 3) were given to the patients who are below 30 years.

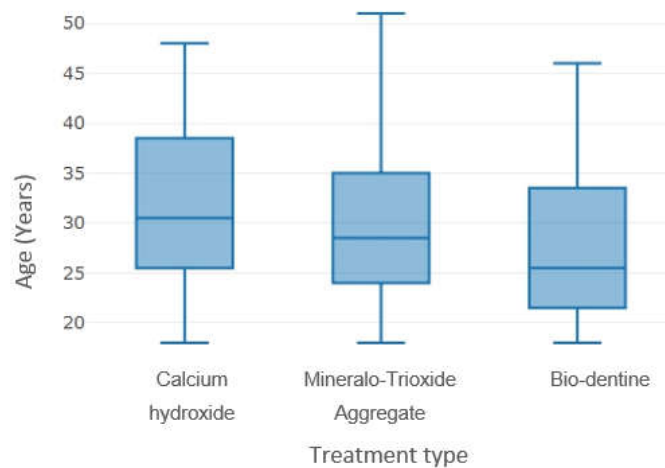


Fig. 5. The variation of the treatment type with age

The p-values obtained using the Wilcoxon Rank Sum Test are given in Table 1. This suggests that there is no significant difference between the three treatments.

Table 1. The results of the Wilcoxon Rank Sum Test for checking the significance difference between the Treatment types

	Treatment-1 and Treatment-2	Treatment-1 and Treatment-3	Treatment-2 and Treatment-3
w-value	209.5	227.5	213.5
p-value	0.8065	0.2943	0.514

Several models were obtained using different variance function classes provided in *nlme* library in the statistical software R. AIC and BIC values obtained for the fitted models are given in Table 2.

Table 2. AIC and BIC values for homoscedastic and heteroscedastic models

		AIC	BIC	Log Likelihood
Homoscedastic Model	Model A	2962.31	2999.25	-1471.16
Heteroscedastic Model	Model B	2962.53	3006.85	-1469.26
	Model C	2948.87	2985.81	-1464.44
	Model D	2951.38	2999.39	-1462.69
	Model E	2937.23	2977.86	-1457.61
	Model F	2957.14	2997.77	-1467.57
	Model G	2959.53	3000.16	-1468.76
	Model H	3100.65	3141.28	-1539.33
	Model I	2963.32	3003.95	-1470.66
	Model J	2644.27	2699.68	-1307.14

Model A, the homoscedastic model (Table 2) was fitted using the variables time, age, treatment type and their two-variable interaction terms.

Fixed effect for model A is the area of the infected region which is explained by time, treatment and age with the interaction between time and treatment (interactions between only 2 variables) while the random effect is explained for each group where grouping is given by the patient number.

Table 3. CCC and TDI values for models

	Homoscedastic model		
	Treatment 1 and Treatment 2	Treatment 1 and Treatment 3	Treatment 2 and Treatment 3
CCC values	0.905	0.909	0.874
TDI values	3.148	4.390	1.647
	Heteroscedastic model		
CCC values	0.989	0.990	0.975
TDI values	2.963	4.388	1.457

Model J was selected as the best model since AIC and BIC values obtained using model J are the lowest compared to the particular values of the other models. It can be concluded that the area of the infected region depends on the age of the patient, time periods, treatment type and their two-variable interaction terms. There is a positive impact on the area of the infected region by the interaction between the treatment type and age. There are negative impacts on the area of the infected region by the treatment type, age, time and the interaction between the treatment type and time. According to the model summaries, the highest negative impact on the area of the infected region is caused by the treatment type.

In order to assess the agreement between three treatment types, CCC and TDI values were obtained (Table 3). From both CCC and TDI values given in Table 3, a strong positive agreement is observed between all three treatments.

4 Discussion

In the present study, the data of 60 patients who were subjected to endodontic treatment for anterior teeth was investigated. They have selected the patients exhibiting well circumscribed periapical lesions of more than 5mm in diameter on a pre-operative periapical radiograph. Akinyamoju et al. [22] found that the age range of the patients having periapical lesions was 9 to 80 years with a peak at age group of 20-29 years. In the present study, we obtained the similar results reconfirming the fact as given in Fig. 4. Furthermore they have found that, females were more frequently affected by this condition. The present study has been reported the similar observations as in Fig. 6.

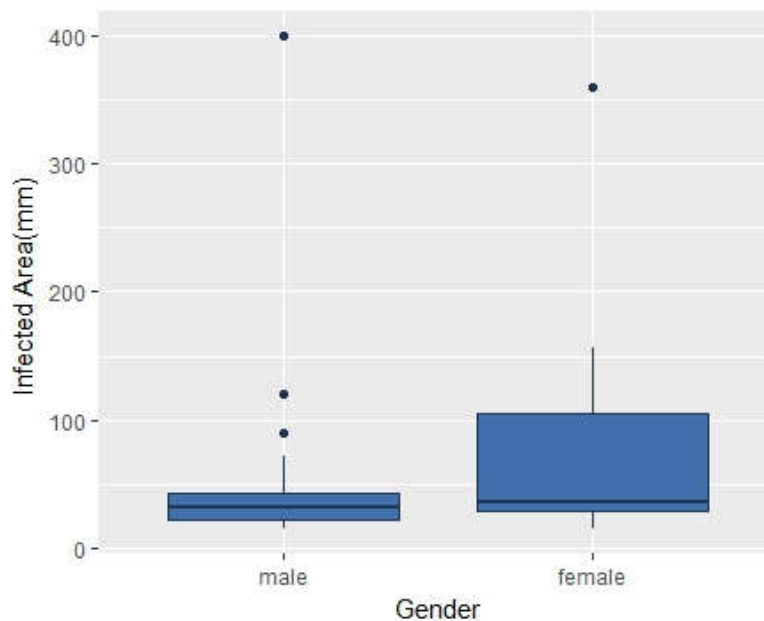


Fig. 6. Variation of Infected area with gender

A similar study was carried out by Dexon et al. [23] and the three treatments they compared are Photo Activated Disinfection(PAD), triple antibiotic paste and the calcium hydroxide where all three were used as root canal disinfectant. Moreover, in their study they have found that there is a significant change between calcium hydroxide and PAD using Kruskal-Wallis Test and Bonferroni post hoc test. In the present study the two treatments being compared with the treatment 1 (calcium hydroxide) differ from the previously mentioned study. Although the above-mentioned study has reported a significant difference between the two treatments, no significant difference was found among any of the treatments we considered. As denoted in the Table 1, the p-values obtained using the Wilcoxon Rank Sum Test which are greater than 0.05 suggests that there is no significant difference between the three treatments. Therefore, the present study has used mixed effects model analysis to compare the three treatment types.

The standard mixed-effects model is successful in explaining the data set, in accordance with the literature. The presence of heteroscedasticity is indicated by the situations where the key assumptions such as constant error variance (homoscedastic error variance) are violated. Therefore, in the present study, a multiple

heteroscedastic mixed effects model is proposed to model the data and this fitted model is then used to assess the agreement between multiple methods of measurements. This methodology has been indicated by Nawarathna et al. [24,25] as a way of measuring agreement in method comparison studies with heteroscedastic measurements.

Bland et al. [26] affirmed that use of correlation is misleading in comparison of a new measurement technique with an established one. Furthermore they have suggested an alternative approach based on graphical techniques and simple calculations. In the current study this evaluation was done using Concordance Correlation Coefficient and Total Deviation Index where the correlation coefficient is taken into account.

In this study, we only considered 60 patients for the analysis. The results would be more accurate, if the sample size had been increased. Further, simple random sampling was used with no specific attention to the gender. Therefore, future studies may include responsiveness of the treatment conditional on gender.

5 Conclusion

The two treatments; with Mineralo-Trioxide Aggregate and Bio-dentine agreed sufficiently well with the standard reference method with Calcium hydroxide and hence all three treatments can be used interchangeably. Moreover, the agreement between the treatments using Calcium hydroxide and Bio-dentine is higher compared to the agreements between the other treatments namely Calcium hydroxide with Mineralo-Trioxide Aggregate and Biodentine with Mineralo-Trioxide Aggregate.

Acknowledgements

Authors wish to acknowledge the support from the Faculty of Dental Sciences, University of Peradeniya for data collection and granting us access to utilize data for this study.

Competing Interests

Authors have declared that no competing interests exist.

References

- [1] Möller AJ, Fabricius L, Dahlén G, Ohman AE, Heyden G. Influence on periapical tissues of indigenous oral bacteria and necrotic pulp tissue in monkeys. *Scand J Dent Res.* 1981;89:475–84.
- [2] Juerchott A, Pfefferle T, Flechtenmacher C, et al. Differentiation of periapical granulomas and cysts by using dental MRI: a pilot study. *Int J Oral Sci.* 2018;10(2):17.
DOI: 10.1038/s41368-018-0017-y.
- [3] Çalışkan MK, Şen BH. Endodontic treatment of teeth with apical periodontitis using calcium hydroxide: A long-term study. *Endod Dent Traumatol.* 1996;12:215–21.
- [4] Nair PNR, Pajarola G, Schroeder HE. Types and incidence of human periapical lesions obtained with extracted teeth. *Oral Surg Oral Med Oral Pathol Oral Radiol Endod.* 1996;81:93–102.
- [5] Schulz M, von Arx T, Altermatt HJ, Bosshardt D. Histology of periapical lesions obtained during apical surgery. *J Endod.* 2009; 35:634–42.
- [6] Fernandes M, de Ataíde I. Nonsurgical management of periapical lesions. *J Conserv Dent.* 2010;13(4):240–245.
DOI: 10.4103/0972-0707.73384.

- [7] Salamat K, Rezai RF. Nonsurgical treatment of extraoral lesions caused by necrotic nonvital tooth. *Oral Surg Oral Med Oral Pathol.* 1986;61:618–23.
- [8] Lin LM, Huang GT, Rosenberg PA. Proliferation of epithelial cell rests, formation of apical cysts, and regression of apical cysts after periapical wound healing. *J Endod.* 2007;33:908–16.
- [9] Halıtkan MK. Prognosis of large cyst-like periapical lesions following nonsurgical root canal treatment: A clinical review. *Int Endod J* 2004;37:408-16.
- [10] Soares J, Santos S, Silveira F, Nunes E. Nonsurgical treatment of extensive cyst like periapical lesion of endodontic origin. *Int Endod J.* 2006;39(7):566-75.
- [11] Murphy WK, Kaugars GE, Collet WK, Dodds RN. Healing of periapical radiolucencies after nonsurgical endodontic therapy. *Oral Surg Oral Med Oral Pathol.* 1991;71:620–4.
- [12] Fernandes M, de Ataıde I. Nonsurgical management of periapical lesions. *J Conserv Dent.* 2010; 13(4):240–245.
DOI: 10.4103/0972-0707.73384.
- [13] Morse DR, Bhambani SM. A dentist’s dilemma: Nonsurgical endodontic therapy or periapical surgery for teeth with apparent pulpal pathosis and an associated periapical radiolucent lesion. *Oral Surg Oral Med Oral Pathol.* 1990;70:333–40.
- [14] Çalışkan MK, Şen BH. Endodontic treatment of teeth with apical periodontitis using calcium hydroxide: A long-term study. *Endod Dent Traumatol.* 1996;12:215–21.
- [15] Al Khasawnah Q, Hassan F, Malhan D, et al. Nonsurgical clinical management of periapical lesions using calcium hydroxide-iodoform-silicon-oil paste. *Biomed Res Int.* 2018;8198795.
- [16] Chhabra N, Singbal KP, Kamat S. Successful apexification with resolution of the periapical lesion using mineral trioxide aggregate and demineralized freeze-dried bone allograft. *J Conserv Dent.* 2010;13:106.
- [17] Kunhappan S, Kunhappan N, Saraf KK, Kridutt V. Nonsurgical endodontic treatment of teeth associated with large periapical lesion using triple antibiotic paste and mineral trioxide aggregate apical plug: A case series. *J Conserv Dent.* 2017;20:141-5.
- [18] Sarang S, Deepak P, Dhirendra S, Shibani G, Shubha RD. Large periapical or cystic lesions in association with roots having open apices managed nonsurgically using 1-step apexification based on platelet-rich fibrin matrix and biodentine apical barrier: A case series. *Journal of Endodontics.* 2018;44.
DOI: 10.1016/j.joen.2017.08.036.
- [19] Dassanayake ID, Nawarathna LS. Assessing inter-rater agreement between multiple medical instruments with heteroscedastic measurements. *J Med Stat Inform.* 2017;5(1).
- [20] Nawarathna LS. Heteroscedastic models for method comparison data. PhD Thesis, ProQuest Dissertations Publishing. 2014;3634471.
- [21] Aravind KR, Nawarathna LS. A statistical method for assessing agreement between two methods of heteroscedastic clinical measurements using the copula method. *J Med Stat Inform.* 2017;5:3.
- [22] Akinyamoju AO, Gbadebo SO, Adeyemi BF. Periapical lesions of the jaws: A review of 104 cases in ibadan. *Ann Ib Postgrad Med.* 2014;12(2):115–119.

- [23] Johns DA, Varughese JM, Thomas K, Abraham A, James EP, Maroli RK. Clinical and radiographical evaluation of the healing of large periapical lesions using triple antibiotic paste, photo activated disinfection and calcium hydroxide when used as root canal disinfectant. *Journal of Clinical and Experimental Dentistry*. 2014;6(3):230-236.
- [24] Nawarathna LS, Choudhary PK. Measuring agreement in method comparison studies with Heteroscedastic measurements. *Statistics in Medicine*. 2013;32(29):5156–5171.
- [25] Nawarathna LS, Choudhary PK. A heteroscedastic measurement error model for method comparison data with replicate measurements. *Statistics in Medicine*. 2015;34(7):1242–1258.
- [26] Bland JM, Altman DG. Statistical methods for assessing agreement between two methods of clinical measurement. *Lancet*. 1986;i:307-310.

© 2019 Lakmali et al.; This is an Open Access article distributed under the terms of the Creative Commons Attribution License (<http://creativecommons.org/licenses/by/4.0>), which permits unrestricted use, distribution, and reproduction in any medium, provided the original work is properly cited.

Peer-review history:

The peer review history for this paper can be accessed here (Please copy paste the total link in your browser address bar)

<http://www.sdiarticle3.com/review-history/50952>