



# Unilateral Sixth Nerve Palsy Unveiling a Giant Nasopharyngeal Tumor: A Rare Case of Neuro Ophthalmic Presentation

**S. Sadiki <sup>a\*</sup>, K. Sifnasr <sup>b</sup>, I. Tazi <sup>c</sup>, S. Sebbata <sup>a</sup>, Y. Achegri <sup>a</sup>,  
S. Salama <sup>a</sup>, A. Fiqhi <sup>a</sup>, Y. Mouzari <sup>a</sup> and A. Oubaaz <sup>a</sup>**

<sup>a</sup> *Department of Ophthalmology, Military hospital Mohamed V, Rabat, Morocco.*

<sup>b</sup> *Department of Radiology, Military hospital Mohamed V, Rabat, Morocco.*

<sup>c</sup> *Department of Anatomic Pathology, Military hospital Mohamed V, Rabat, Morocco.*

## **Authors' contributions**

*This work was carried out in collaboration among all authors. All authors read and approved the final manuscript.*

## **Article Information**

### **Open Peer Review History:**

This journal follows the Advanced Open Peer Review policy. Identity of the Reviewers, Editor(s) and additional Reviewers, peer review comments, different versions of the manuscript, comments of the editors, etc are available here:

<https://www.sdiarticle5.com/review-history/116159>

**Case Report**

**Received: 27/02/2024**

**Accepted: 30/04/2024**

**Published: 06/05/2024**

## **ABSTRACT**

Nasopharyngeal tumor is an intrusive tumor arising from the epithelium of the nasopharynx, presenting as different symptoms depending on the area of the development of the tumor. It is an endemic carcinoma in North Africa. The location of the tumor, its difficult access to the physical examination and the symptomatology often misleading associated with invasion of adjacent structures explain the often delayed diagnosis.

The purpose is to report a rare neuro-ophthalmic presentation of nasopharyngeal carcinoma. We report the case of a 60 years old woman who first presented with a sixth nerve palsy leading to the diagnosis of a giant nasopharyngeal tumor extending to the cavernous sinus.

\*Corresponding author: E-mail: [sadi.samah@gmail.com](mailto:sadi.samah@gmail.com);

**Keywords:** Nasopharyngeal tumor; abducens; diplopia; cavernous sinus.

## 1. INTRODUCTION

Nasopharyngeal carcinoma is one of the most frequent cancers in North Africa. The most common histological type is non-keratinising squamous cell carcinoma.

The intracranial extension may be revealed by cranial nerve paralysis or orbital apex syndrome. Cranial nerve involvement isn't rare but the isolated sixth nerve paralysis as first presentation of the tumor is uncommon.

## 2. CASE PRESENTATION

We report the case of a 70 years old female, with no history of diabetes or cardiovascular disease who presented with a 4-week history of limited eye movement plus diplopia.

The ophthalmological examination found limitation in abduction of the left eye and an horizontal

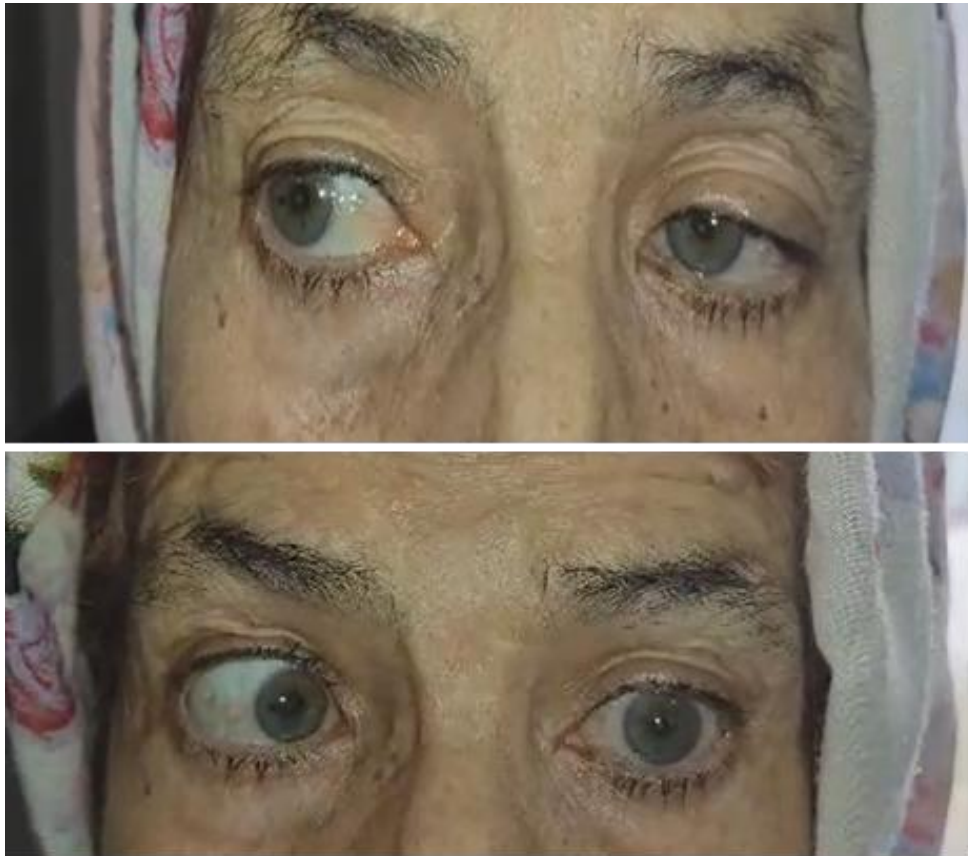binocular diplopia worsened with left gaze (Fig. 1).

The best-corrected visual acuity (BCVA) was 20/25 in both eyes, pupil was reactive and equal. Exam of the anterior and posterior segment were unremarkable.

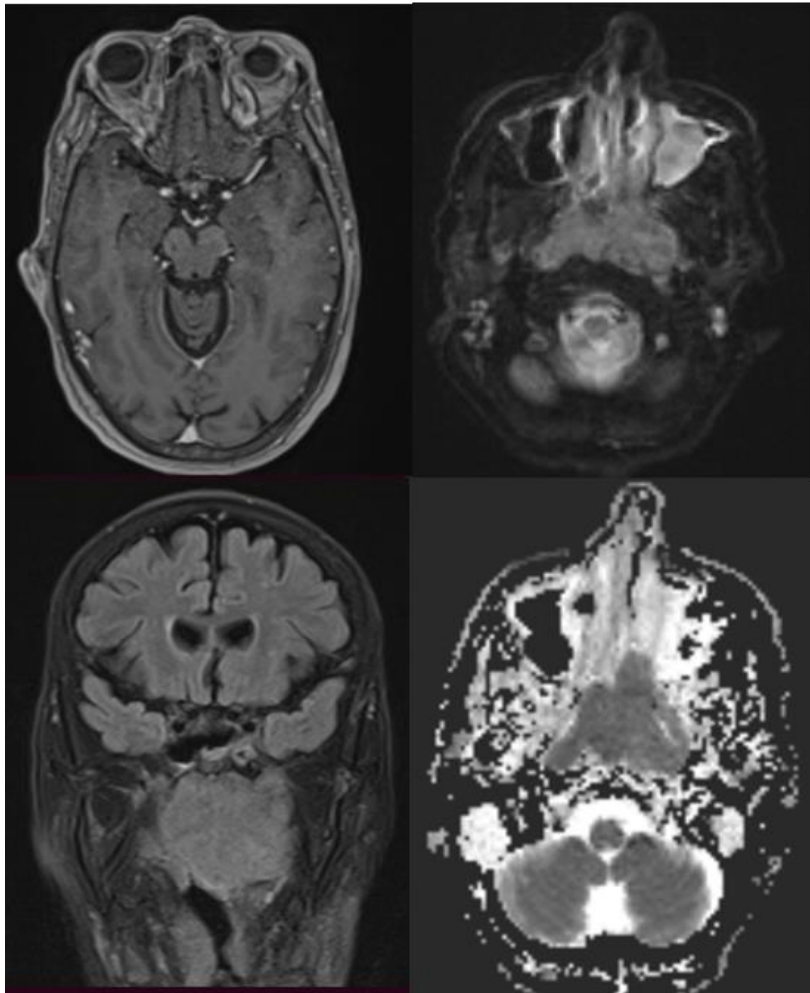
Orbitocerebral magnetic resonance imaging (coronal and axial slices) was performed and showed a giant left nasopharyngeal tumor starting to extend to the left cavernous sinus (Fig. 2).

The patient was referred to an otolaryngologist who performed a rhinoscopy that showed a mass at the left nasopharynx. Tumor biopsy was done and revealed a non keratinizing squamous cell carcinoma (Fig. 3).

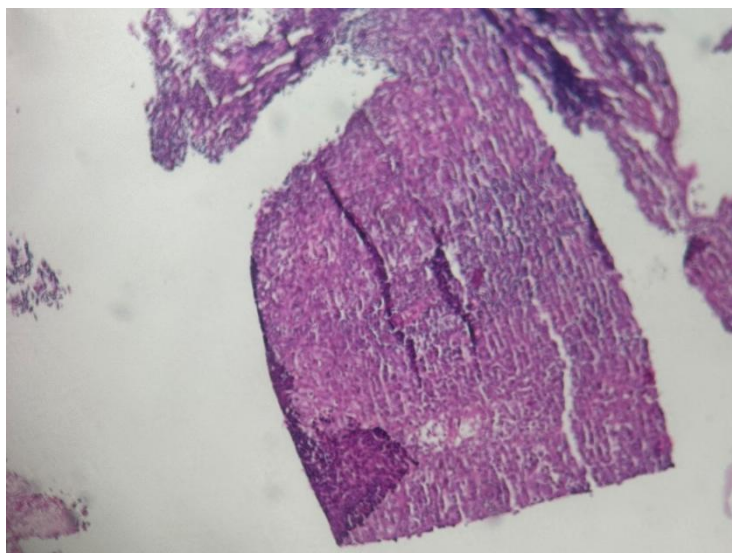
The patient was then addressed to the oncology department and started the radiotherapy followed by chemotherapy .



**Fig. 1. Patient examination showed significant abduction deficit of the left eye**



**Fig. 2. Giant nasopharyngeal tumor : Isosignal on T1 sequences , hypersignal on diffusion sequences with low ADC with significant enhacement after gadolinium injection**



**Fig. 3. Histopathological examination revealing a non keratinizing squamous cell carcinoma**

### 3. DISCUSSION

Nasopharyngeal tumors are frequent tumors in North Africa with an incidence rate of 8-12/10000. The tumor occurs in the epithelial lining of the nasopharynx .On a pathological basis , there are 3 histological types and the undifferentiated nonkeratinizing NPC is the most common type [1] .

Almost half of the clinical presentations of the nasopharyngeal tumor are nasal symptoms although other symptoms may be present depending on the extension .

Cranial nerve palsy represents 9,4% of NPC symptoms [2] .Cranial neuropathy is usually associated with a more invasive stage T4 which explains the poor prognosis in cranial nerve involvement [3].The cranial nerves that are the most involved are nerve V (particularly the maxillary division) and VI [4].A study conducted by Richards and Al found that NPC was responsible for abducens palsy in (5.6%) out of 193 patients presenting with ocular motor nerve palsy caused by intracranial neoplasms.

In most cases in literature, abducens palsy associated with diplopia is only present as a sign of the recurrence of the tumor or post-radiotherapy.Kau and al analysed a series of patients presenting diplopia secondary to the tumor .They found that the new onset of diplopia in these patients was secondary to tumor recurrence in (52%) of the patients , radiation neuropathy in (35%), and skull base osteoradionecrosis in (13%) [5].

Wong and Al analysed data of 354 patients diagnosed with or treated for NPC a.7.6% of the patients presented an ophthalmic involvement due to NPC or its treatment.Symptomatic orbital invasion occurred in 48.1%. Ocular signs, but no

orbital invasion, was present 29.6%. [6]. However cavernous sinus infiltration was not statistically significant as a factor of poor prognosis in patients treated for NPC, even in advanced lesions [7].

CT scan supplemented with MRI is currently being used for accurate tumor mapping and detection of possible tumor extension [7].

In a series of 166 patients , Ilhan and al tried to analyse the outcome of abducens nerve paralysis in patients with nasopharyngeal carcinoma.The third nerve palsy was associated with poor outcome compared to the sixth nerve palsy, which is more amenable to treatment [8].The duration of neuropathy and the involvement of the optic nerve were independent negative predictors for neurological recovery because of the irreversible damage to the neural tissue, even if the underlying cause is addressed [9].

Nasopharyngeal tumors are not abordable for surgery because of the anatomical specificity of the region, but it is a highly radiosensitive tumor.Radiotherapy or chemoradiotherapy is considered the first choice treatment for NPC [10].

According to several studies, NPC misdiagnosis can be attributed to two causes: patient delay and health system issues (professional delay) [11]. Improper diagnosis and a lack of suspicion of NPC by healthcare professionals, particularly in low-incidence areas, contribute to late diagnosis [12]. The anatomical specificity of the tumor is also related to a late diagnosis. .James and Al reported a median time of 2 months between apparition of symptoms and diagnosis of NPC in a serie of 504 patients [13,14,15].

**Table 1. Different clinical symptoms of nasopharyngeal carcinoma [2]**

Structures	Clinical presentation
Nasal	Nasal obstruction/Epistaxis
Aural	-Hearing loss -Tinnitus
Neurological	-Diplopia ( Sixth nerve) -Ophtalmoplegia ( Cranial nerves ) -Horner's syndrome -Xerophthalmia [15]
Metastasis	-Cervical lymph node - Paraneoplastic syndrome

#### 4. CONCLUSION

Nasopharyngeal carcinoma is among the most frequently misdiagnosed tumors since it does not initially present with nasal symptoms. While early optic nerve involvement is extremely rare, symptoms are associated with cranial involvement. To improve patient survival, NPC should be diagnosed early and any isolated nerve palsy should lead to neuroimaging.

#### CONSENT

As per international standard or university standard, patient(s) written consent has been collected and preserved by the author(s).

#### ETHICAL APPROVAL

It is not applicable.

#### COMPETING INTERESTS

Authors have declared that no competing interests exist.

#### REFERENCES

1. Agrawal A, Baisakhiya NV Sj, J Sr. Nasopharyngeal Carcinoma Presenting with Cavernous Sinus Involvement. Trigeminal Neuralgia and Middle Ear Effusion; 2009.
2. Lekskul A, Thanomteeranant S, Tangtamaruk P, Wuthisiri W. Isolated sixth nerve palsy as a first presentation of nasopharyngeal carcinoma: A case series. *Int Med Case Rep J.* 2021;14:801–808.  
DOI: 10.2147/IMCRJ.S334476
3. Hernandy Yuliawan H, Kartika A, Hanindya Sari R. Abducens nerve palsy as the first manifestation of nasopharyngeal malignancy.
4. Chow JCH et al. Cranial neuropathies in advanced nasopharyngeal carcinoma: Neurological recovery after modern radiotherapy and systemic chemotherapy. *Radiotherapy and Oncology.* Oct. 2021; 163:221–228.  
DOI: 10.1016/j.radonc.2021.08.022
5. Kau HC, Tsai CC. New onset diplopia in patients with nasopharyngeal carcinoma following concurrent chemoradiotherapy: Clinical features and etiology. *Biomed Res Int.* 2015;2015.  
DOI: 10.1155/2015/735173.
6. Aghdam KA Zand A, Sanjari MS. Isolated unilateral sixth nerve palsy in a patient with nasopharyngeal carcinoma. *Rom J Ophthalmol.* Dec. 2019; 63(4):375–378.  
DOI: 10.22336/rjo.2019.59
7. Leung SF, Tsao SY, Teo P, Foo W. Clinical oncology original article cranial nerve involvement by nasopharyngeal carcinoma: Response to treatment and clinical significance; 1990.
8. Gupta R, Mohindroo NK, Azad R. Nasopharyngeal carcinoma with an uncommon presentation. *Int J Head Neck Surg.* 2017;8(1):34-36.
9. Wendy Meihua Wong, Stephanie Ming Young, Shantha Amrith: Ophthalmic involvement in nasopharyngeal carcinoma, *Orbit*; 2017.
10. Liao J-F, Ma L, Du X-J, Lan M, Guo Y, Zheng L, et al. Prognostic Value of Cavernous ; 2016.
11. Sinus invasion in patients with nasopharyngeal carcinoma treated with intensity-modulated radiotherapy. *PLoS One.* 2016; 11(1): e0146787.  
DOI: 10.1371/journal.pone.0146787
12. Ding JH, Hu CS, Peng WJ, Zhou ZR, Tang F, Mao J. Evaluation of MRI in nasopharyngeal carcinoma with cavernous sinus infiltration. *Zhonghua Zhong Liu Za Zhi.* 2006;28:530–2.  
PMID: 17147120
13. Patel SV, Mutyala S, Leske DA, Hodge DO, Holmes JM. Incidence, associations, and evaluation of sixth nerve palsy using a population-based method. *Ophthalmology* 2004;111(2):369–75.  
Available: <https://doi.org/10.1016/j.ophtha.2003.05.024>
14. Marlinda Adham., et al. Delayed diagnosis of nasopharyngeal carcinoma in a patient with early signs of unilateral ear disorder.

- Medical Journal of Indonesia. 23.1 2014:52-57. patient with nasopharyngeal carcinoma. Rom J Ophthalmol. 2019; 63(4):375–8.
15. Aghdam KA, Zand A, Sanjari MS. Isolated unilateral sixth nerve palsy in a Available: <https://doi.org/10.22336/rjo.2019.59>.

© Copyright (2024): Author(s). The licensee is the journal publisher. This is an Open Access article distributed under the terms of the Creative Commons Attribution License (<http://creativecommons.org/licenses/by/4.0>), which permits unrestricted use, distribution, and reproduction in any medium, provided the original work is properly cited.

*Peer-review history:*  
*The peer review history for this paper can be accessed here:*  
<https://www.sdiarticle5.com/review-history/116159>